

**POMEGRANATE – A DOUBLE EDGED SWORD FOR
THROMBOLYSIS AND OXIDATIVE STRESS****Shalini H. Kumar¹ and Pushpa A.^{2*}**

¹Research Scholar, Department of Biochemistry, Biotechnology and Bioinformatics,
Avinashilingam Institute for Home Science and Higher Education for Women, Coimbatore,
Tamil Nadu, India.

²Professor Department of Biochemistry, Biotechnology and Bioinformatics, Avinashilingam
Institute for Home Science and Higher Education for Women, Coimbatore, Tamil Nadu,
India.

Article Received on
10 Feb 2016,

Revised on 20 March 2016,
Accepted on 31 March 2016

DOI: 10.20959/wjpr20164-6019

***Correspondence for
Author****Dr. Pushpa A.**

Professor Department of
Biochemistry,
Biotechnology and
Bioinformatics,
Avinashilingam Institute
for Home Science and
Higher Education for
Women, Coimbatore,
Tamil Nadu, India.

ABSTRACT

The well recognized thrombolytic potential of the fruits of *Punica granatum* in vitro has influenced furthermore to confirm its clot lysing ability in vivo. In the current study, thrombolytic efficiency of the aril and rind of the fruits of pomegranate was analysed in the thrombus induced rat models. The ability of the extract to lyse the preformed clot was confirmed through the haematological profile, antioxidant status and histopathological examination of liver, heart and tail of experimental rats. The extracts of *Punica granatum* exhibited remarkable thrombolysis.

KEYWORDS: Thrombolysis; *Punica granatum*; Antioxidant; histopathology

INTRODUCTION

Acute myocardial infarction, stroke and venous thromboembolism that comprises cardiovascular diseases, can lead not only to sudden death but also to long-term disability at a large cost to society. Thrombus formed in the blood vessel can be dissolved with thrombolytic agents whose safety remains unanswered with several drawbacks such as systematic bleeding, short half-life and long term use is difficult.^[1] The risks and hurdles associated with the currently used thrombolytic agents such as tPA

outweighs the purported benefits as thrombolytic agent, demanding an urge for sources with both antioxidant and thrombolytic property.

In most cases, it is not possible to obtain human samples from the site of thrombosis to study the disease and so it is advantageous for researchers to use animal models to investigate thrombosis in biological setting. The use of thrombosis models in rodents plays a crucial role in bridging the bench to bedside transition.^[2] The carrageenan induced tail thrombosis model in rats is useful for evaluating compounds having antithrombotic effects in drug discovery projects.^[3] The kappa carrageenan is a most potent thrombogen. As a consequence of thrombosis, tail infarction becomes visible few minutes after administration of carrageenan.^[4]

A surge in free radical production facilitating a vicious cycle that impinges on mitochondrial dysfunction, excitotoxicity, lipid peroxidation and inflammation is observed during ischemia as well as reperfusion.^[5] During reperfusion, oxidative stress reaches higher peaks and has a more sustained duration than other pathogenic mechanisms of ischemic cell death, further supporting the need for research of antioxidant therapies in reperfused individuals.^[6] Consequently, any plant source that has both clot lysing efficacy and excellent antioxidant potential will be the choice of interest since the fruit can overcome the ill effects caused by oxidative stress during reperfusion. Interestingly, pomegranate has well recorded antioxidant potential and its clot lysing efficiency is also proved in vitro. Therefore the present study was carried out with the aril and rind of pomegranate to ensure its thrombolytic efficiency in vivo.

MATERIALS AND METHODS

Collection and preparation of extracts

The fruit sample was collected from the Coimbatore city and certified by the Botanical Survey of India, Coimbatore. The voucher specimen was collected and maintained. The aril and rind of fresh fruits were collected, washed and homogenized using distilled water for the preparation of aqueous extract. It was then filtered using Whatmann No 1 filter paper and used for further study.

Evaluation of in vivo clot lysis in rat models:

In vivo studies were carried out by the oral administration of aril and rind of *Punica granatum* to examine the clot lysing ability and antioxidative effect to the experimental rats.

Maintenance of experimental animals

Male Swiss Albino rats were procured from Bangalore and were housed in microloan boxes in a controlled hygienic environment at temperature $25 \pm 2^\circ\text{C}$ and 12 hr dark/light cycle. The study was conducted after obtaining institutional animal ethical committee's clearance (IAEC No: KMCRET / Ph.D / 12/ 2014 – 15). As per the standard practice, the rats were segregated and quarantined for 15 days before the commencement of the experiment. They were fed on standard healthy diet and water *ad libitum*. The acute toxicity studies carried out confirmed that the extracts are not toxic even at the concentration of 5000 mg/kg.

Grouping of animals

The rats were divided into seven groups with six rats in each. The groupings are as follows:

GROUPS	DESCRIPTION	EXTRACT / DRUG DOSE
I	Control	-
II	κ – carrageenan only	-
III	κ – carrageenan + Streptokinase	30,000 IU
IV	κ – carrageenan + PgAA	250 mg/kg
V	κ – carrageenan + PgRA	250 mg/kg

PgAA – *P. granatum* Aril Aqueous ; PgRA - *P. granatum* Rind Aqueous

Thrombus induction

Experimental rats were anaesthetized with i.p injection of ketamine hydrochloride (100 mg/kg). To attain effective clot formation κ – carrageenan (1 mg/kg) dissolved in saline was injected into the rat tail vein at a site 12 cm from the tip of the tail with a ligation. After a period of 10 minutes, the ligature was removed. The length of the infarct was monitored for thrombus formation. Once thrombus was formed, the animals were treated with respective extracts and monitored for the reduction in the length of the thrombus in rat tail for 30 days.

Haematological Parameters

At the end of the study, the rats were sacrificed after an overnight fasting. The blood of the animals was collected by heart puncture and the serum separated was used for the estimation of haematological parameters associated with thrombolysis.

S.No	PARAMETERS	SOURCE	METHOD
1	Haemoglobin	Citratd Blood	Drabkin and Austin, 1932 ^[7]
2	RBC		Sanderson and Phillips, 1981 ^[8]
3	Platelet		
4	WBC		
5	Neutrophils		Automated Cell counter – CD1700
6	Monocytes		

In vivo antioxidant potential

An oxidative stress is induced during clot formation and reperfusion, increasing the generation of free radicals. Thus, determining the tissue antioxidant status is essential to understand the effect of extracts on rats.

A part of the liver and kidney homogenate was prepared using PBS and used for the determination of enzymic and non-enzymic antioxidants. Antioxidants namely catalase, superoxide dismutase, glutathione peroxidase, vitamin C and reduced glutathione were then assessed in the liver and kidney of the experimental rats.

Catalase - Catalase activity in the tissue homogenate was assayed by the method of Sinha (1972).^[9]

Superoxide dismutase - Superoxide dismutase activity in the tissue was determined by Kakkar (1984).^[10]

Glutathione peroxidase - Glutathione peroxidase activity was determined by the method of Rotruck et al.^[11]

Vitamin C - Ascorbic acid, a scavenger of oxyradicals was estimated by the method of Omaye et al., 1979.^[12]

Reduced glutathione - Reduced glutathione, an intermediary redox metabolite in the ascorbate - glutathione cycle of scavenging hydrogen peroxide, was estimated according to the procedure described by Moron et al. (1979).^[13]

Histopathological examination

Liver, heart and tail were removed from experimental animals and transferred to ice cooled containers with 10% formalin solution for histopathological observation (Culling, 1979).^[14]

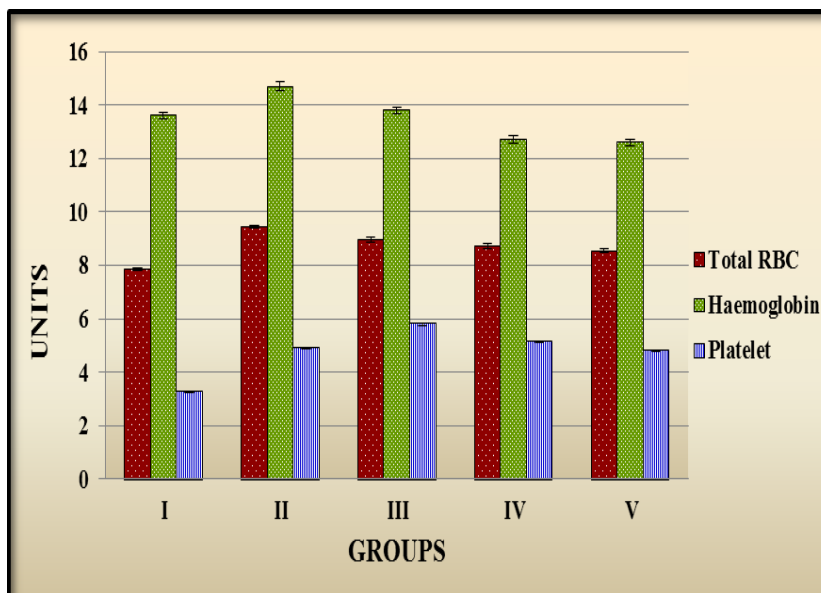
RESULTS AND DISCUSSION**Haematological parameters**

The pathology and physiology of man and animals when exposed to any foreign substance is first reflected in the blood components and the parameters usually analysed are haemoglobin, RBCs and WBCs. Blood form an important index for risk evaluation in both humans and rodents. So blood from all rats were analysed for components namely RBC, haemoglobin,

platelets, WBC, monocytes and neutrophils to study its association with thrombosis and thrombolysis. The results are tabulated in figure 1 and table 1.

Figure 1

Level of RBCs, platelets and haemoglobin in experimental rats



RBC is expressed as 10^6 cells/ μ l,

Haemoglobin is expressed as g/dl,

Platelet is expressed as 10^5 cells/ μ l

Total red blood cell count and haemoglobin levels revealed a similar pattern among all groups. It was found that the RBCs and haemoglobin increased when a thrombus is formed but the level remained well within the normal range. The primary thrombus formation is a critical phenomenon that involves activation of platelets and thereby platelet aggregation. RBCs that are generally regarded as innocent bystanders do play a significant role during thrombus formation and the mechanism of action needs further investigation.^[15]

Platelet count was found to increase when a thrombus was formed and subsequently increased when treated with both the extract and standard streptokinase. The increase in the level of platelets when treated with the extracts were lower when compared with that of the drug, streptokinase. This marginal increase could be credited for the reocclusion, a major drawback in thrombolytic therapies. McRedmond et al.^[16] reported that streptokinase activates platelets, thereby limiting its efficiency as a thrombolytic agent. In contrast, the level of platelets did not increase significantly when treated with fruit extracts, proving its safety and thrombolytic efficiency in vivo.

Table: 1 Level of WBCs, monocytes and neutrophils in experimental rats

Groups	Treatments	WBCs ³ x10 ³ / μ l	Neutrophils ³ x10 ³ / μ l	Monocytes ³ x10 ³ / μ l
I	Control	11.65 \pm 0.15	0.032 \pm 0.002	2.95 \pm 0.06
II	Thrombus induced	14.50 \pm 0.21 ^a	0.05 \pm 0.001	3.29 \pm 0.07 ^a
III	Streptokinase Treated	13.50 \pm 0.12 ^{ab}	0.044 \pm 0.003	3.10 \pm 0.11
IV	PgRA Treated	13.75 \pm 0.16 ^{ab}	0.038 \pm 0.001	2.85 \pm 0.09 ^b
V	PgAA Treated	13.45 \pm 0.17 ^{ab}	0.039 \pm 0.004	2.91 \pm 0.05 ^b
Normal values		6.6 – 12.6	0.01 - 0.04	1.77 – 3.38

PgRA – Punica granatum rind aqueous

PgAA – Punica granatum aril aqueous

An increase in total WBC count and neutrophils was found in thrombus induced groups while they fell towards normalcy when treated with streptokinase and fruit extracts. The level of monocytes was within the normal range among the groups that were analysed.

Literatures support the fact that there is WBC infiltration in the first 12 hours after myocardial infarction, thereby promoting tissue damage. Following ischaemia, neutrophils are involved in the inflammatory response. Barbu et al.^[17] have reported that leukocytosis; an increase in WBC count appears to be a potential threat factor for thrombosis. An elevation of WBC count during acute myocardial infarction is associated with adverse outcomes such as reduced epicardial blood flow, thromboresistance, new congestive heart failure and even death. A systemic inflammatory reaction is induced due to thrombus formation and consequent vein wall damage in deep vein thrombosis patient and as a consequence, increased level of WBCs was observed.^[18]

Antioxidant potential

A surge in free radical production is observed during ischemia/reperfusion resulting in a further increase in oxidative stress and tissue damage. During reperfusion, oxidative stress reaches higher peaks and has a more sustained duration than other pathogenic mechanisms of ischemic cell death, further supporting the need for research of antioxidant therapies in reperfused individuals.^[6]

Therefore, the risks and hurdles associated with the currently used thrombolytic agents such as tPA overshadows the supposed benefits as thrombolytic agent, demanding an urge for sources with both antioxidant and thrombolytic property. Therefore, the effect of Punica

granatum in the antioxidant status of animals was determined in kidney and liver. Activity of enzymic antioxidants namely catalase, superoxide dismutase and glutathione peroxidase and levels of non-enzymic antioxidants such as vitamin C, vitamin E and reduced glutathione were evaluated and the results are as tabulated in tables 2 and 3.

From the results it was observed that the fruit extract conferred good antioxidant protection against the oxidative stress that was found to be peaked during the thrombus formation and lysis. A significant increase in the levels of non-enzymic antioxidants and activity of enzymic antioxidants were noted in animals treated with *Punica granatum* pulp extracts than rind extracts.

Nekooeian^[19], showed that the pomegranate seed oil decreased the oxidative stress without affecting the serum lipid profile. Moneim et al.^[20] reported a significant increase in superoxide dismutase and catalase activities of liver and kidney samples of rats that received pomegranate. Chalfoun-Mounayar et al.^[21] reported that pomegranate molasses possesses a powerful antioxidant activity with increased superoxide dismutase activity.

Table: 2 Activity of enzymic antioxidants in experimental rats

Groups	CAT (U/g protein)		SOD (U/g protein)		GPx (U/g protein)	
	Kidney	Liver	Kidney	Liver	Kidney	Liver
I	813.55 \pm 25.33	743.63 \pm 34.83	346.44 \pm 23.26	293.91 \pm 16.01	13.00 \pm 0.95	14.59 \pm 0.84
II	632.23 \pm 25.76 ^a	541.65 \pm 24.81 ^a	267.34 \pm 25.76 ^a	277.64 \pm 15.19	6.07 \pm 0.81 ^a	14.76 \pm 0.29
III	710.21 \pm 35.47 ^{ab}	579.76 \pm 37.19 ^a	375.59 \pm 41.03 ^b	268.66 \pm 21.35	8.36 \pm 0.34 ^{ab}	12.54 \pm 0.48 ^{ab}
IV	889.95 \pm 20.45 ^{abc}	882.90 \pm 12.24 ^{abc}	417.16 \pm 14.66 ^{ab}	355.41 \pm 13.84 ^{abc}	15.36 \pm 0.46 ^{abc}	21.88 \pm 0.42 ^{abc}
V	923.20 \pm 20.28 ^{abc}	964.00 \pm 26.17 ^{abcd}	372.38 \pm 19.52 ^b	372.00 \pm 16.59 ^{abc}	16.49 \pm 0.57 ^{abc}	19.15 \pm 0.69 ^{abcd}

CAT – Catalase

SOD – Superoxide Dismutase

GPx – Glutathione Peroxidase

Table: 3 Level of non-enzymic antioxidants in experimental rats

Groups	VITAMIN E (μ g/ g tissue)		VITAMIN C (mg/ g tissue)		REDUCED GLUTATHIONE (nmoles/g tissue)	
	Kidney	Liver	Kidney	Liver	Kidney	Liver
I	2.78 \pm 0.07	2.41 \pm 0.05	0.22 \pm 0.001	0.35 \pm 0.014	10.29 \pm 0.13	12.57 \pm 0.15
II	1.85 \pm 0.06 ^a	2.04 \pm 0.03 ^a	0.18 \pm 0.005	0.184 \pm 0.005	7.54 \pm 0.18 ^a	6.87 \pm 0.19 ^a
III	1.75 \pm 0.09 ^a	2.12 \pm 0.04 ^a	0.15 \pm 0.006	0.172 \pm 0.007	7.27 \pm 0.24 ^a	7.05 \pm 0.13 ^a
IV	3.14 \pm 0.11 ^{abc}	3.08 \pm 0.09 ^{abc}	0.25 \pm 0.009	0.375 \pm 0.008 ^{bc}	10.98 \pm 0.17 ^{abc}	12.03 \pm 0.18 ^{bc}
V	3.52 \pm 0.13 ^{abc}	3.49 \pm 0.12 ^{abc}	0.29 \pm 0.013	0.392 \pm 0.006 ^{bc}	12.76 \pm 0.19 ^{abcd}	14.86 \pm 0.14 ^{abcd}

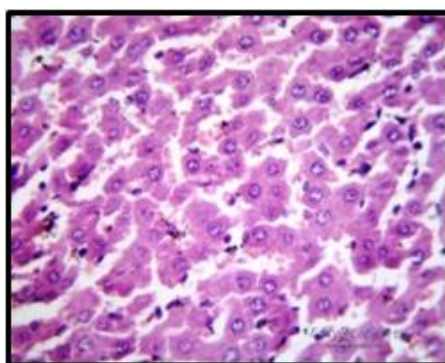
A sensible strategy and a herculean task that must be adopted before a costly translational research is to explore newer antioxidant drug which must show recognisable additive or synergistic effects with thrombolytic agents in thromboembolic models.^[22] The results of the present study confirm the same and collectively signify that the fruit *Punica granatum* has an augmentive effect on thrombolysis by rendering good oxidative protection with its numerous antioxidants.

HISTOPATHOLOGICAL CHANGES IN EXPERIMENTAL RATS

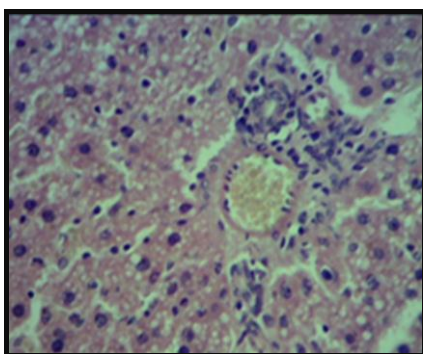
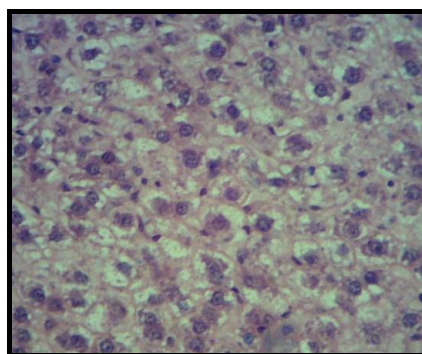
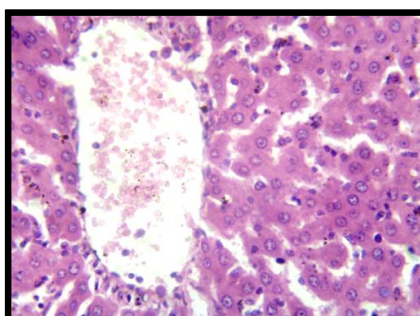
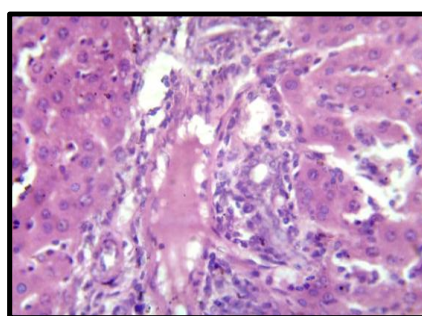
Histopathological examinations of liver, heart and tail of control and experimental rats of the various groups studied was carried out to test the cytotoxicity and clot lysing effect of the aril and rind of *Punica granatum*. The cellular changes are indicated in figures 2, 3, 4 and the findings are discussed below.

Altogether, there was no major change in histopathology of the tissues in the treated groups confirming that the extracts did not render any cytotoxic effect. Moreover, the tail histology validated the thrombolytic efficiency of the fruit *Punica granatum*.

Alferah in 2012^[23] studied the toxicity induced by *Lawsonia inermis* leaf extract and the subsequent histological changes in liver and kidney of male wistar rats. Moderate degenerative changes in epithelium lining in renal tubes and distortion and degeneration of hepatocytes were observed. No pathological observations were made when a medicinal plant extract (Ankaferd Blood Stopper) was applied in deep tissue injury in rats.^[24]



Group I

**Group III****Group II****Group IV****Group V****Figure 2 Histopathological observations of liver of experimental animals**

Group I – Histology of liver sections of control animals showed normal lobular architecture.

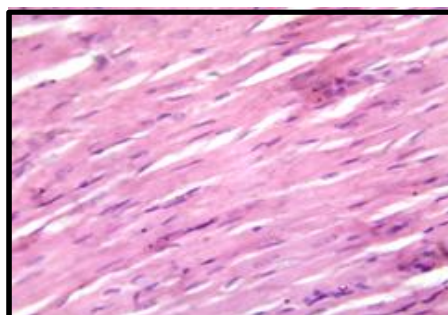
The hepatocytes were intact with no periportal inflammation and the portal triad was normal.

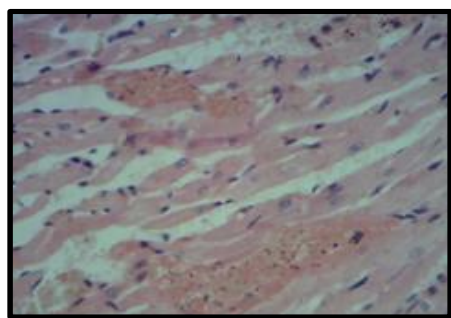
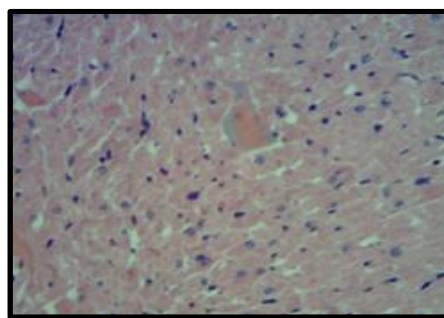
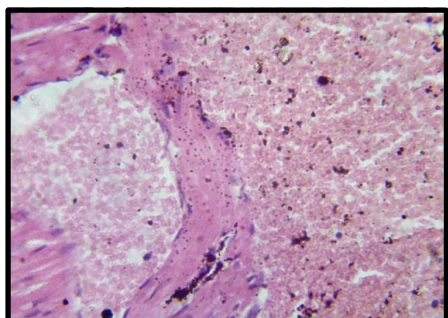
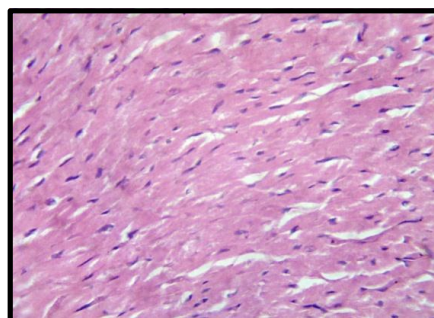
Group II – The hepatocytes maintained normal lobular architecture with mild portal tract inflammation. Microvesicular steatotic hepatocytes were also seen with no cholestralsosis.

Group III – The sections showed pale steatotic area with central vein and extensive microvesicular fatty change.

Group IV – The cells showed mild alterations in the lobular architecture with very mild inflammation.

Group V – There were no alterations in the architecture in the liver section. Only a mild inflammation was detected.

**Group I**

**Group II****Group III****Group IV****Group V****Figure: 3 Histopathological observations of heart of experimental animals**

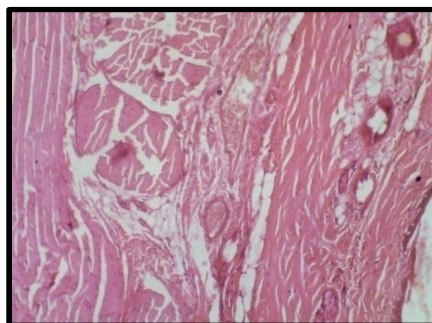
Group I – Histological sections of heart showed normal myocardium with no inflammation or necrosis.

Group II – The myocardium showed congested veins and mild chronic inflammation. Anisonucleosis and nucleomegaly of myocardium were also observed.

Group III – Congested vessels in myocardium and few necrotic muscle fibres were observed

Group IV – The cells showed congested vessels with normal myocardium.

Group V – There were no alterations in the architecture in the heart section. The myocardium was normal with no chronic inflammation.

**Group I**

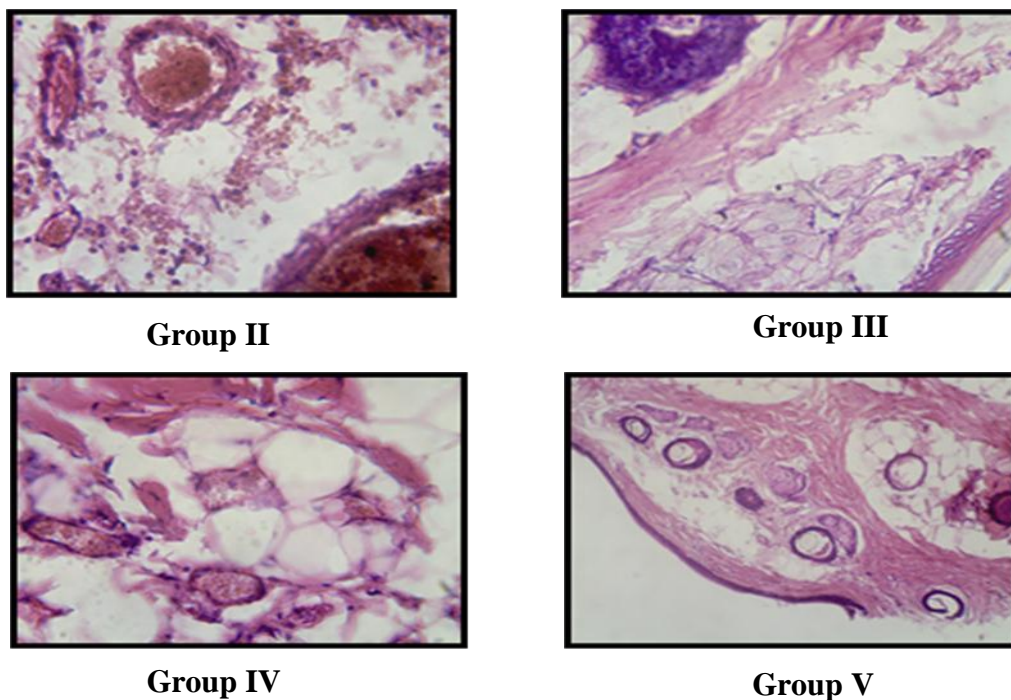


Figure: 4 Histopathological observations of tail of experimental animals

Group I – Histological sections of tail showed normal epidermis, dermis with normal blood vessels and hair follicles.

Group II – The histopathological observations of tail showed congested blood vessels with edema and mild inflammation. Thick and thin walled vessels with fibrocollagenous stroma were observed.

Group III – Normal blood vessels, dermis and epidermis were observed. The dermis showed normal proliferation of blood vessels.

Group IV – The skin showed congestion with edema and congested blood vessel.

Group V – There was no evidence of toxic changes. There was slight lymphocyte infiltration.

Literatures reveal that urokinase plasminogen activator; a thrombolytic drug activates oxidative stress. Supplementation with pomegranate juice reduces the effect of thrombosis and it shows plasminogen activation. With a plethora of shortcomings and negativity of the available thrombolytic therapies, these modest findings of the present study gain significance in employing the fruit *Punica granatum* for efficient clot lysis.

CONCLUSION

Oxidative stress is the key root for several lifestyle associated diseases in today's world. Pomegranate, which was extensively exploited for its antioxidant potential has now been recognized as a double edged sword which has potent thrombolytic efficiency as well.

However, further investigations are warranted to have a profound insight into the mechanism of action of the fruit for thrombolysis.

REFERENCES

1. Bang J, Lee KM, Kim B, Lee J, Lee IS, Jeon WK. Anti-thrombotic Effects of Modified Jeho-tang using a FeCl₃-induced Carotid Arterial Thrombosis Model. *J Korean Med.*, 2013; 34(2): 51-58.
2. Diaz JA, Obi AT, Myers DD, Wroblewski SK, Henke PK, Mackman N, Wakefield TW. Critical review of mouse models of venous thrombosis. *Arterioscl Thromb Vasc Biol.*, 2012; 32(3): 556-562.
3. Hagimori M, Kamiya S, Yamaguchi Y, Arakawa M. Improving frequency of thrombosis by altering blood flow in the carrageenan-induced rat tail thrombosis model. *Pharm Res.*, 2009; 60(4): 320-323.
4. Kishore, K. In vitro and in vivo screening methods for antithrombotic agents. *Am J Phytomed Clin Therap*, 2013; 1(5): 497-506.
5. Crack PJ, Taylor JM. Reactive oxygen species and the modulation of stroke. *Free Rad Biol Med.*, 2005; 38: 1433-1444.
6. Liu KJ, Rosenberg G. Matrix metalloproteinases and free radicals in cerebral ischemia. *Free Rad Biol Med.*, 2005; 39: 71-80.
7. Drabkin DL, Austin JM. Spectrophotometric constants for common haemoglobin derivatives in human, dog and rabbit blood. *J Biol Chem.*, 1932; 98: 719-733.
8. Sanderson, JH, Philips CE. An atlas of laboratory. Animal haematology, Clarendon Press, Oxford, 1981; 473.
9. Sinha KA. Colorimetric assay of catalase. *Ann Biochem*, 1972; 47: 389-394.
10. Kakkar P, Das B, Viswanathan PN. A modified spectrophotometric assay of SOD. *Ind J Biochem Biophys*, 1984; 21: 130-132.
11. Rotruck JT, Pope AL, Ganther HE, Swanson AB. Selenium: Biochemical roles as a component of glutathione peroxidase. *Science*, 1984; 179: 588-590.
12. Omaye ST, Turbul TD, Sauberlich HC. Selected method for the determination of ascorbic acid in animal cells, tissues and fluids, Mc. Cormic, D.B, Wright, D.L. (eds), *Methods of enzymology*, Academic Press, New York, 1979; 3-11.
13. Moron MS, De Pierre JN, Mannervik V. Levels of glutathione, glutathione reductase, glutathione-S-transferase activities in rat lung and liver. *Biochem Biophys Acta*, 1979; 582: 67-68.

14. Culling CFA. Handbook of histopathological and histochemical techniques. 3rd edition, New York, Butterworth and Co. Ltd., 1979; 7.
15. Brown GE, Ritter L, McDonagh PF, Cohen Z. Functional enhancement of platelet activation and aggregation by erythrocytes: Role of red cells in thrombosis. *Peer J Pre Prints*, 2014; 351(v1): 20 pages.
16. McRedmond JP, Harriott P, Walker B, Fitzgerald DJ. Streptokinase-induced platelet activation involves antistreptokinase antibodies and cleavage of protease-activated receptor-1. *Blood*, 2000; 95: 1301-1308.
17. Barbui T, Carobbio A, Rambaldi A, Finazzi G. Perspectives on thrombosis in essential thrombocythemia and polycythemia vera: Is leukocytosis a causative factor? *Blood.*, 2009; 114(4): 6.
18. Reiter M, Bucek BA, Koca N, Dirisamer A, Minar E. Deep vein thrombosis and systemic inflammatory response: A pilot trial, *Wiener Klinische Wochenschrift.*, 2003; 115(3-4): 111-114.
19. Nekooeian AA. Effects of pomegranate seed oil on insulin release in rats with type 2 diabetes. *Iran J Med.*, 2014; 39(2): 130-135.
20. Moneim AAE, Dkhil MA, Al-Quraishy S. Studies on the effect of pomegranate (*Punica granatum*) juice and peel on liver and kidney in adult male rats. *J Medic Plants Res.*, 2011; 5(20): 5083-5088.
21. Chalfoun-Mounayar A, Nemr R, Yared P, Khairallah S, Chahine R. Antioxidant and weight loss effects of pomegranate molasses. *J App Pharm Sci*, 2012; 2(6): 45-50.
22. Amaro S, Chomorro A. Translational stroke research of the combination of thrombolysis and antioxidant therapy. *Stroke*, 2011; 42: 1495-1499.
23. Alferah MAZ. Toxicity induced histological changes in selected organs of male (Wistar) rats by *Lawsonia inermis* leaf extract. *Eur J Med Plants*, 2012; 2(2): 151-158.
24. Okumuş M, Yüksel KZ, Özbağ D, Çiralık H, Yılmaz Z, Gümüşalan Y, Bakan V, Kalender AM. Medicinal plant extract (Ankaferd Blood Stopper) application in deep tissue injuries in rats: Histopathological investigation of the effect on regional and systemic tissues. *Turk J Trau Emerg Surg*, 2013; 19(1): 1-7.
25. Fuhrman B, Khateeb J, Shiner M, Nitzan O, Karry R, Volkova N, Aviram M. Urokinase plasminogen activator upregulates paraoxonase 2 expression in macrophages via an NADPH oxidase-dependent mechanism. *Art. scl, Thromb Vasc Biol.*, 2008; 28: 1361-1367.