

ABORTIFACIENT EFFICACY OF *MORINGA OLEIFERA* STEM BARK ON FEMALE ALBINO RATS

Varsha Zade* and Dinesh Dabhadkar

Department of Zoology, Government Vidarbha Institute of Science and Humanities,
Amravati 444604, Maharashtra, India

Article Received on
12 March 2014,

Revised on 05 April 2014,
Accepted on 28 April 2014

***Correspondence for
Author**

Dr. Varsha S. Zade

Department of Zoology,
Government Vidarbha Institute
of Science and Humanities,
Amravati, Maharashtra, India -
444604.

INTRODUCTION

Several potential approaches for induction of infertility have been investigated over a long period including hormonal, chemical and immunological approaches (Gupta and Sharma, 2006). Family planning has been promoted through several methods of contraceptions, but due to serious adverse effects produced by synthetic steroidal contraceptions (Farnsworth et al., 1975), attention has been focused on indigenous plants for possible contraceptive effect. Medical abortion has emerged as a valuable alternative to surgical abortion and will contribute to safe reproductive control worldwide (Reynolds, 1996; Gan et al., 2008). The quest for the oral contraceptive agents that can control human fertility is as old as recorded history. A wide variety of synthetic contraceptive agents are

available (Bygdeman et al., 1997) but these cannot be used continuously due to their severe side effects. (Vervest and Haspels, 1985) Hence people are now looking back to age old traditions of using herbal contraceptive medicines which have minimum side effects. *Moringa oleifera* (Linn) is a medicinally important plant, belonging to family *Moringaceae*. The plant is also well recognized in India, Pakistan, Bangladesh and Afghanistan as a folkloric medicine (Mughal et al., 1999). *Moringa oleifera* is a small or medium sized tree up to 10 m tall, with thick, soft, corky, deeply fissured bark, growing mainly in semiarid, tropical and subtropical areas (Mughal et al., 1999). Different parts of the tree have been used in the traditional system of medicine. Survey in the tribal belt of Melghat region (20° 51' to 21° 46' N and to 76° 38' to 77° 33' E) of Amravati district of Maharashtra state of India revealed that *Moringa oleifera* stem bark is being used traditionally as an abortifacient. The stem bark has been used in indigenous medicine for over many decades as traditional

medicine. The seeds are also known to exert its protective effect by decreasing liver lipid peroxides and, as an antimicrobial agent (Lalas and Tsaknis, 2002). The stem bark of *Moringa oleifera* are used as purgative, applied as poultice to sores, rubbed on the temples for headaches, used for piles, fevers, sore throat, bronchitis, eye and ear infections, scurvy and cataract; leaf juice is also believed to control glucose levels and applied to reduce glandular swelling (Faizi et al., 1998; Morton, 1991; Dahot, 1988). The stem bark is used as an antioxidant (Makonnen et al., 1997; Ghasi et al., 2000). The root of *Moringa oleifera* were shown to possess antihelmithic, rubefacient, carminative, antifertility, anti-inflammatory, stimulant in paralytic afflictions; as a cardiac/circulatory tonic, used as a laxative, abortifacient, in treatment of rheumatism, inflammations, articular pains, lower back or kidney pain and constipation (Nath and Sethi, 1992; Padmarao et al., 1996).

However, there is no information to substantiate or refute the abortifacient claims of *Moringa oleifera* stem bark in the scientific literature. Therefore, the present work has been undertaken to validate scientifically the abortifacient role of *Moringa oleifera* stem bark as acclaimed by the traditional tribal users of Melghat region.

MATERIALS AND METHODS

Collection of Plant Material

The stem bark of *Moringa oleifera* plant (Family: *Moringaceae*) were collected from Melghat region of Amravati district during the period of September to December 2012. The plants parts were identified and authenticated by experts from Botanical Survey of India, Pune (Accession No. VZ- 1).

Procurement and Rearing of Experimental Animal

Healthy wistar strain female albino rats about two month old and weighing 150- 250 g were procured from Sudhakar Rao Naik Institute of Pharmacy, Pusad (Maharashtra). The rats were housed in polypropylene cages and maintained under environmentally controlled room provided with a 12:12 hr light and dark cycle approximately at 25 °C. They were fed on pellets (Trimurti Lab Feeds, Nagpur) and tap water *ad libitum*. The rats were allowed to acclimatize to laboratory environment for 15 days before experimentation.

All experimental protocols were subjected to the scrutinization and approval of Institutional Animal Ethics Committee [registration number 1060/ac/07/ CPCSEA (IAEC/1/2012)].

Preparation of Extract

All the plant material were collected, shade dried, powdered and subjected to soxhlet extraction successively with distilled water, ethanol, diethyl ether and benzene for abortifacient activity. The extract was evaporated to near dryness on a water bath, weighed and kept at 4 °C in refrigerator until use.

Phytochemical Screening

The presence of various plant constituents in the plant extract were determined by preliminary phytochemical screening as per Thimmaiah (1999).

Acute Toxicity Study

Healthy female albino rats were starved for 3- 4 hrs and subjected to acute toxicity studies as per Organization of Economic Co-operation and Development (OECD) guidelines No: 423 (OECD, 2004). They were divided into 5 groups of 6 animals each and kept singly in separate cages during the experiment. Group 1 represented the control group, which received 10 ml/kg of distilled water orally. Groups 2- 5 received suspension of different extract (aqueous, alcohol, benzene and diethyl ether) of *Moringa oleifera* stem bark orally at the doses of 250, 500 and 1000 mg/kg daily for 7 days respectively. The rats were observed continuously for 2 hrs for behavioral, neurological and autonomic profile, and for next 24 and 72 hrs for any lethality or death.

Abortifacient Activity

The plants extracts were tested in female albino rats for abortifacient activity as per Khanna and Choudhary (1968). The vaginal smears of caged female rats of known fertility were monitored daily. Unstained material was observed under a light microscope. The proportion among the cells observed was used for determination of the estrous cycle phases (Long and Evans, 1952). The female rats in pro-estrous phase were caged with males of proven fertility in the ratio of 2:1, in the evening and examined the following day for the evidence of copulation. Rats exhibiting thick clump of spermatozoa in their vaginal smear were separated and that day was designated as day 1 of pregnancy. These rats were randomly distributed into 13 groups, one control group and 12 experimental groups of 6 animals each. On the day 10 of pregnancy animals were laprotomised under light ether anaesthesia using sterile conditions. The two horns of uteri were examined to determine the implantation sites. Thereafter the abdominal wound was sutured in layers. The extract to be tested were then fed to operated pregnant rats i.e. aqueous, alcoholic, diethyl ether and chloroform extracts of *Moringa*

oleifera stem bark at doses of 25, 50, 100 mg/kg body weight (one tenth of the highest tolerable dose) once daily by an intragastric (i. g.) soft rubber catheter from day 11 up to the 15th day of pregnancy. The animals were allowed to go full term. After delivery the pups were counted and the abortifacient activity of extract was evaluated. The following parameters were computed: number of live and dead fetuses; % survival ratio= (number of live fetus/number of live+ dead fetus) \times 100; resorption index= (total number of resorption sites/total number of implantation sites) \times 100; postimplantation loss= (number of implantations-number of live fetuses/ number of implantations) \times 100. The anogenital distance (AGD) and crown rump length (CRL) of litters were measured by using a measuring tape. The variations in birth weight of litters and gestation period between control and experimental animal was also determined to check the abortive effect of plants (Abdulazeez et al., 2009).

Histopathological Studies

The ethanolic extract at 100 mg/kg dose was found most active among all the four treatments groups; hence it was subjected to detail investigation for histopathological study. After 30 days of treatment, ovaries and uterus of animals belonging to control and experimental group were dissected out and immediately fixed in 10 % buffered neutral formalin solution. After fixation, tissues were embedded in paraffin, serial sections were cut at 5 μ , stained with hematoxylin and eosin, examined for histoarchitectural changes and photographed under Olympus BX51 light microscope (Kosif, 2008).

Statistical Analysis

All the data are expressed as mean \pm S.E. Statistical analysis was done by Student's t-test and one way ANOVA (Mahajan, 1997).

RESULTS

Preliminary phytochemical screening of *Moringa oleifera* stem bark revealed the presence of alkaloid, steroids, flavanoids, phenolics compound and saponins respectively. The highest dose 1000 mg/kg body weight of *M. oleifera* stem bark extract was used for acute toxicity activity. Clinical toxicity symptoms such as respiratory distress, salivation, weight loss and change in appearance of hair as well as maternal mortality were not observed at any period of the experiment. Similarly no mortality and changes in the behavioural, neurological and autonomic profile were observed in all extract treated groups. This suggested that short term use for this purpose is apparently safe.

Moringa oleifera stem bark extract has a folklore reputation as abortive. In the present study the extracts when tested for abortifacient effect in laboratory animals, exhibited abortive activities in accordance. The oral administration of alcoholic extract of *Moringa oleifera* stem bark at the doses of 25, 50 and 100 mg/kg body weight produced a dose dependent adverse effect on fertility index and number of implantation in the uterine horns of the female rats by virtue of an increase in the percentage of the post-implantation embryonic loss. All the experimental extract when evaluated for their abortifacient activity, were found to exhibit pregnancy interceptive activity. Administration of 100 mg/kg body weight of the alcoholic extract resulted in 100% abortion, while doses of 50 and 25 mg/kg body weight of the alcoholic extract resulted in 44.86 % and 26.26 % abortion. This was evident from decrease in the percentage of live fetuses. The percent resorption index increased from zero in the control animals to 100 % in 100 mg/kg body weight alcoholic extract treated animals. The present investigation also revealed that the aqueous, benzene and diethyl ether extract exhibit abortifacient activity ranging from 10 % to 47.9 % (Table- 1). All the treatment reduced significantly the number of litters born, confirming the abortifacient activity of the plant used. No vaginal bleeding was observed. The litter born to the experimental animal did not show any morphological defects hence, it can be stated that the treatment does not exhibit any teratogenic effect.

The litter size of control group rats was the highest (7.5 ± 0.50) but there was a decrease in litter size with increase in the dose of the extract of plant *M. oleifera* in all the treatment groups. However the litter body weight recorded in animals administered with alcoholic, aqueous, benzene and diethyl ether extract of *M. oleifera* stem bark were not significantly different from control. The AGD to CRL ratio of the litter of rats dosed with experimental plant extract at various doses of 25, 50 and 100 mg/kg body weight were similar to that of control group. Similarly, the total body length of litters at day 1 of birth also did not vary significantly from that of control. When the sex ratios of litter were determined it was found that the male sex was dominant to female sex. The gestation period did not show any variation in extract treated group of animals as compared to control group (Table- 2). Further, the dose dependent increase in the resorption index due to the administration of the experimental extract, in the present study is an indication of failure in the development of the embryo. Such occurrences of foetal resorption suggest that interruption of pregnancy occurred after implantation of the foetus.

Histopathological Study

Ovary

The cellular organization of the ovary of control rats presented normal features as evidenced by the presence of all types of follicles, few atretic follicles, with normal vascularity in compact stroma and a well developed graffian follicle (Fig. 1a). The histological section of the ovary of rats when treated with 100 mg/kg ethanolic stem bark extract of *M. oleifera* showed lesion and there was degeneration in the ovarian cortex and vasculations in the stroma cells. Mature follicle underwent atresia, detachment of granulosa layer occurred. Theca externa and theca interna were separated from the follicle. There was an increase in the number of atretic follicles (Fig. 1b).

Uterus

The uterine histology of the control rat presented normal architecture. The endometrium exhibited large epithelial cells having basal and middle nuclei with a spongy layer filled with blood vessels and uterine glands lined by epithelial cells. The uterine glands were numerous, irregular and tortuous. The uterine lumen was highly distended and the stroma was loose with normal vascularity (Fig. 2c). The histological section of the ovary of rats when treated with 100 mg/kg ethanolic stem bark extract of *M. oleifera* showed shrinkage of uterine gland and shows absence of extensive folding of luminal epithelium, musculature was highly affected, stroma was compact with poor vascularity (Fig. 2d).

Table 1: Effect of aqueous, ethanol, benzene and diethyl ether extract of *M. oleifera* (stem bark) on fertility of female rats when fed orally from day 11 to 15 of pregnancy

Treatment groups	Dose (mg/kg body wt)	No. of foetus individual rats on day 10	No. of rats delivered (litter size)	No. of resorption in individual rats	No. of resorption (mean±SE)	Aborti-facient activity (%)
(Group- 1) Control	Vehicle	8,8,9,8,6,6	6(8,8,9,8,6,6)	0,0,0,0,0,0	0	Nil
(Group- 2 to 4) Aqueous extract	25	7,7,5,8,7,9	6(6,7,5,6,5,9)	1,0,0,2,2,0	0.83±0.24**	11.11
	50	9,9,10,7,7,8	6(7,6,9,4,4,6)	2,3,1,3,3,2	2.33±0.28***	29.37
	100	4,8,6,8,8,8	6(0,6,3,5,6,4)	4,2,3,3,2,4	3.33±0.60***	47.9
(Group- 5 to 7) Ethanolic extract	25	10,6,8,7,9,8	6(9,4,5,4,7,6)	1,2,3,3,2,2	2.16±0.18**	26.26
	50	9,9, 8,10,8,10	6(6,6,4,5,3,6)	3,3,4,5,5,4	4.00±0.58***	44.86
	100	3,6,2,8,6,4	6(0,0,0,0,0,0)	3,6,2,8,6,4	4.83±0.80***	100

(Group- 8 to 10) Benzene extract	25	7,9,7,7,8,9	6(6,8,6,4,8,9)	0,1,1,2,0,0	0.66±0.13***	10
	50	9,7,8,8,10,7	6(8,6,7,6,9,7)	1,1,1,2,1,0	1.00±0.04**	11.9
	100	6,5,7,7,5,6	6(5,4,6,5,4,5)	1,1,1,2,1,1	1.16±0.30***	19.3
(Group- 11 to 13) Diethyl ether extract	25	8,10,9,8,7,8	6(8,8,9,7,6,8)	0,2,1,1,0,0	0.66±0.33*	11.96
	50	8,8,9,10,11,9	6(7,6,7,8,9,8)	1,2,2,2,2,1	1.66±0.22**	17.93
	100	10,7,8,9,6,7	6(8,3,6,5,3,4)	2,4,2,4,3,3	3.00±0.18***	39.8

Values are expressed as mean ± S.E. from six animals in each group. P values: *<0.05,

<0.01, *<0.001, When compared between group, ns= non significant

Table 2: Effect of aqueous, ethanol, benzene and diethyl ether of *M. oleifera* (stem bark) on the gestation period and litter parameters

Treatment groups	Dose (mg/kg body wt)	Gestation period (days)	Litter size (No.)	Litter body weight (g)	AGD/CRL (mm)	Total body length of litter at 1 st day of birth (mm)	Sex ratio of live fetuses (male/female)	Viable fetuses (%)	Fetus resorptions (Resorption index) (%)
(Group- 1) Control	Vehicle	22.16±0.30	7.5±0.50	4.46±0.06	1.33±0.03	62.3±0.05	24/21	100	0
(Group- 2 to 4) Aqueous extract	25	21.46±0.19 ^b	7.5±0.28 ^a	4.28±0.06 ^b	1.20±0.03 ^a	62.0±0.04 ^a	24/21	89.4	11.11
	50	23.78±0.32 ^a	6.33±0.68 ^b	4.43±0.32 ^a	1.18±0.04 ^a	62.5±0.02 ^{ns}	20/18	70.63	29.37
	100	22.48±0.12 ^{ns}	6.00±0.18 ^c	4.32±0.66 ^b	1.33±0.03 ^a	63.4±0.08 ^b	16/08	52.10	47.9
(Group- 5 to 7) Ethanolic extract	25	23.30±0.98 ^b	5.83±0.80 ^{ns}	4.43±0.30 ^b	1.00±0.07 ^b	63.0±0.03 ^b	18/17	73.74	26.26
	50	21.26±0.66 ^a	5.00±0.78 ^b	5.24±0.28 ^c	1.62±0.10 ^c	64.2±0.02 ^c	19/11	53.14	44.86
	100	0	0	0	0	0	0	0	100
(Group- 8 to 10) benzene extract	25	22.06±0.21 ^a	6.83±0.40 ^{ns}	5.52±0.13 ^c	1.20±0.04 ^a	60.1±0.13 ^a	22/19	90	10
	50	22.68±0.87 ^b	7.16±0.43 ^a	5.23±0.18 ^c	1.42±0.09 ^c	62.5±0.018 ^{ns}	23/20	88.1	11.9
	100	23.67±0.54 ^b	4.83±0.26 ^c	6.00±0.21 ^a	1.08±0.03 ^a	63.5±0.09 ^c	16/13	80.7	19.3
(Group- 11 to 13) diethyl ether extract	25	23.08±0.03 ^c	7.66±0.58 ^{ns}	5.63±0.09 ^{ns}	1.58±0.01 ^b	61.8±0.10 ^{ns}	22/24	88.4	11.96
	50	22.08±0.17 ^{ns}	7.5±0.66 ^c	4.52±0.08 ^b	1.27±0.02 ^a	62.5±0.12 ^b	24/21	82.07	17.93
	100	21.78±0.60 ^c	4.83±0.33 ^b	6.03±0.18 ^c	1.43±0.18 ^{ns}	63.4±0.08 ^c	16/13	60.2	39.8

Values are expressed as mean ± S.E. from six animals in each group. P values: ^a<0.05, ^b<0.01, ^c<0.001, When compared with control, ns = non significant

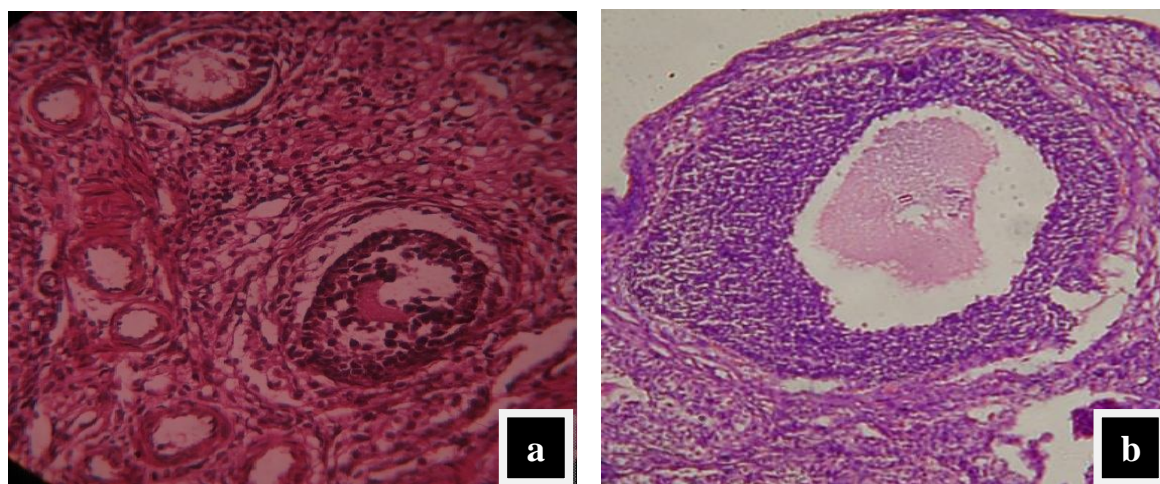


Fig. 1— Photomicrographs of ovarian tissue sections of rats [(a):- Normal ovarian architecture of control rats, (b):- Ovarian architecture of treated rats with ethanolic stem bark extract of *M. oleifera* at dose 100 mg/kg body wt.) Magnification: 100X]

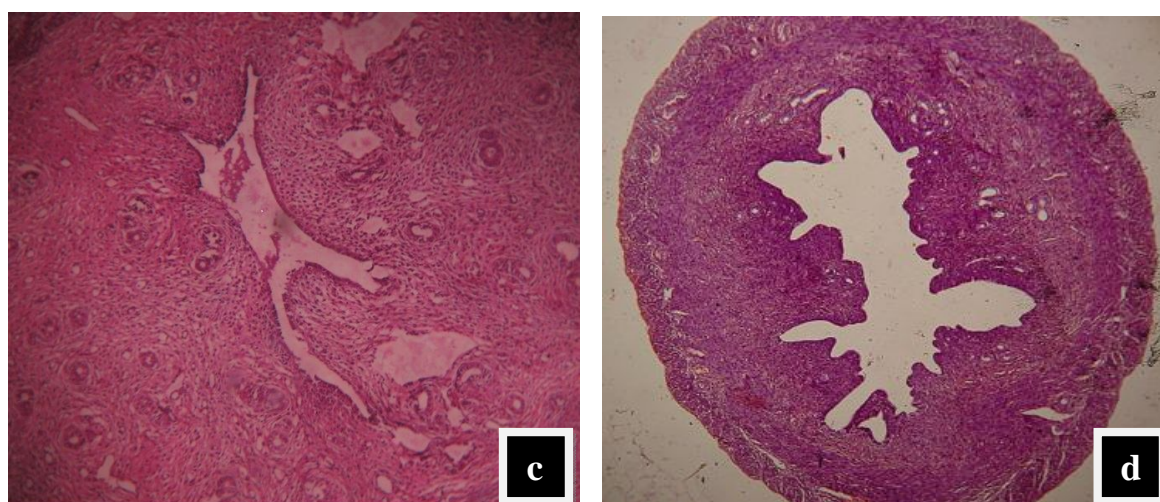


Fig. 2— Photomicrographs of uterus tissue sections of rats [(c):- Normal uterine architecture of control rats, (d):- Uterine architecture of treated rats with ethanolic stem bark extract of *M. oleifera* at dose 100 mg/kg body wt.) Magnification: 100X]

DISCUSSION

In past, many reports have suggested the use of plant extract affecting the reproductive physiology of the animals by reducing survival ratio of fetus (Choudhury et al., 2001; Kamal et al., 2003). Therefore, the increase in the number of dead fetus as well as reduced survival ratio is an indication of the abortifacient activity of the extract. The oral administration of *M. oleifera* stem bark extract (aqueous, alcohol, benzene and diethyl ether) at the doses of 25, 50 and 100 mg/kg body weight resulted in 10 % to 100 % abortion. All these extracts caused significant change in the number of live fetuses and fetal survival percent indicating the possible abortifacient activity of the extract. The result is in agreement with previous finding of Awe et al., (1999), who showed that the methanol extract of the fresh leaves of *Vernonia*

amygdalina, when administered to pregnant mice caused abortion. The fetal loss in the present study is mainly due to the resorption of embryo as there was absence of vaginal bleeding (Amira Kassem, 2006; Geetha et al., 2005). It is evident from the above facts that the aqueous, ethanolic, benzene and diethyl ether extract of *M. oleifera* stem bark contains the compounds which are abortifacient in nature. Our results are also in agreement with that of Zade and Dabhadkar (2012), who reported abortifacient effect of *Plumeria rubra* pods in female albino rats. Aqueous and 90% ethanol leaf extract of *Moringa oleifera* was found to be 100 % abortive at doses equivalent to 175 mg/kg in rats (Nath and Sethi, 1992). In the present work 100 % abortive effect of ethanol extract of stem bark of *Moringa oleifera* at a dose of 100 mg/kg body weight was observed. The antifertility activity of 50 % ethanolic extract of *Moringa oleifera* excluding root was demonstrated in hamster (Dhawan et al., 1980). The antifertility activity of 50 % ethanolic root extract of *Moringa oleifera* was investigated and it was found that a dose of 200 mg/kg led to foetal resorption in 60 % female pregnant rats (Prakash and Mathur, 1976).

In the present investigation there was a decrease in litter size with increase in the dose of the plant *M. oleifera* stem bark extract in all the treatment groups. However the litter body weight recorded in animals administered with alcoholic, aqueous, benzene and diethyl ether extract of *M. oleifera* stem bark were not significantly different from control. The AGD to CRL ratio, the total body length of litters at day 1 of birth and gestation period also did not show any variation in extract treated groups. Further, the dose dependent increase in the resorption index due to the administration of the extract, in the present study is an indication of failure in the development of the embryo. Such occurrences of foetal resorption suggest that interruption of pregnancy occurred after implantation of the foetus (Elbetieha et al., 2000). The results of the present study also revealed that the plant extract was relatively non-embryotoxic as judged by the data on foetal body size and AGD/CRL ratio and the absence of any observable treatment related morphologic defects in the live fetuses. This corroborates with the findings of Schneidereit (1985) on administration of pharma-toxicological substances and Al-bayaty et al., (2011) on administration of *Juniperus phoenicea* fruit extract and Oyesola et al., (2010), while working on aqueous extract of *Aspilula Africana* on fetal organ growth.

In the present study, ovary of rats treated with 100 mg/kg ethanolic stem bark extract of *M. oleifera* showed lesion and there was degeneration in the ovarian cortex and vasculations in

the stroma cells. Mature follicle underwent atresia and detachment of granulosa layer occurred. Theca externa and theca interna were separated from the follicle. There was an increase in the number of atretic follicles or degenerating preovulatory follicle. The degeneration of preovulatory follicles takes place due to non-availability of steroidal hormones. The presence of increased atretic follicles in the rats treated with ethanolic extract of *M. oleifera* indicates that the extract promotes the degeneration of preovulatory follicles (Koneri et al., 2005). Similar result of ovarian retardation was also reported by Madhavi and Saraswati (2011) on administration of *Curcuma longa* extract causing degeneration of ova with many vacuolated spaces. An increase in the atretic follicles and mature follicle undergoing atresia in the treated groups of rats was observed when they were administered with *Cicer arietinum* extract (Wikhe et al., 2013).

Abortion refers to the premature expulsion of the products of conception from the uterus. Abortion may be due to maternal exposure to chemicals, which can disrupt pregnancy and cause detachment of the embryo (Feranades et al., 2010). In the present study, the uterine gland undergoes shrinkage and it shows absence of extensive folding of luminal epithelium, its musculature was highly affected and stroma was compact with poor vascularity. The above changes in the uterine histology, after treatment with the extract may cause the endometrial milieu to become unfavourable for the implantation of the fertilized ovum and hence their antifertility effect. This could be correlated with the previous studies made by Gebrie et al., (2005) on *Rumex steudelii*. Similar result was recorded by Singh (1990) on treatment of female rats with *Sesbania sesban* seeds.

CONCLUSION

The abortifacient activity lends support to the claims for its traditional usage of *Moringa oleifera* stem bark as an abortive medicine. Thus, this study may prove to be an effective and safe alternative remedy for contraception. Further studies to identify the bioactive principle of abortifacient and estrogenic activity of the extract are in progress.

ACKNOWLEDGMENT

Authors are thankful to University Grant Commission, Government of India for funding the present work as a part of the Post doctoral program in the form of Research awards. The authors are grateful to CPCSEA, Chennai, Ministry of Justice and Empowerment, Government of India and IAEC, Government Vidarbha Institute of Science and Humanities, Amravati (M.S) for granting the permission for doing the experimental work on rat.

REFERENCES

1. Abdulazeez MA, Mansurah DA, Ameh AD, Ahmadu D, Ibrahim S, Sani A, Ayo JO, Joseph O, Ambali SF, Suleiman F. Effect of fermented seed extract of *Carica papaya* on litters of female wistar rats. *Afr J Biotechnol*, 2009; 8: 854- 857.
2. Al-bayaty M.A, Saliem AH, Jaafar FR. Antifertility potential of *Juniperus phoenicea* fruits extract in mature female rats. *Al- Qadisiya J Vet Med Sci*, 2011; 10 (1): 1-8.
3. Amira Kassem, Abdulwadi Al- Aghbari, Molham Al- Habori, Al- Mamary. Evaluation of the potential antifertility effect of *fenugreek* seeds in male and female rabbit. *Contraception*, 2006; 73: 301- 306.
4. Awe SO, Makinde JM, Olajide OA. Cathartic effect of the leaf extract of *Vernonia amygdalina*. *Fitoterapia*, 1990; 70: 161- 165.
5. Bygdeman M, Danielson KG, Swalin ML. *Acta Obst Gynecol Scand*, 1997, 76, 75.
6. Choudhary N, Kalita JC, Anasaul H. Effect of *Costus speciosus* Koen on reproductive organ of female albino mice. *Int J Pharmacy*, 2001; 3 (4): 200- 212.
7. Dabhadkar D and Zade V. Abortifacient activity of *Plumeria rubra* (Linn) pod extract in female albino rats. *Indian J Exp Biol*, 2012; 50:702- 707.33.
8. Dahot MU. Vitamin contents of flowers and stem bark of *Moringa oleifera*. *Pak J Biochem*, 1988; 21: 1–24.
9. Dhawan BN, Dubey MP, Mehrotra BN, Rastogi RP and Tondon JS. Screening of Indian plants for biological activity, Part IX. *Indian J Exp Biol*, 1980; 18, 594- 606.
10. Elbetieha A, Oran SA, Alkofahi A, Darmani H, Raies AM. Fetotoxic potential of *Globularia arabica* and *Globularia alypum* (Globulariaceace) in rats. *J Ethnopharmacol*, 2000; 72:215-9.
11. Faizi S, Siddiqui BS, Saleem R, Aftab K, Shaheen F, Gilani AH. Hypotensive constituents from the pods of *Moringa oleifera*. *Planta Med*, 1998; 64: 225–228.
12. Farnsworth NR, Bingel AS, Cordell GA, Crane FA, Fong HH. Potential value of plants as sources of new antifertility agents. *J Phrma Sci*, 1975; 64: 535- 598.
13. Fernandes LCB, Corderio LAV, Blanco BS. *Luffa acutangula* Roxb. Tea promotes developmental toxicity to rats. *J Animal Veterinary Advances*, 2010; 9(8):1255-1258.
14. Gan CY, Zou S, Wu Y, Liu Q. The influence of medical abortion compound with surgical abortion on subsequent pregnancy outcome. *Int J Gynaecol Obstet*, 2008; 101 (3): 231- 238.

15. Gebrie E, Makonnen E, Debellla A, Zerihum L, Phytochemical screening and pharmacological evaluations for the antifertility effect of the methanolic root extract of *Rumex steudelii*, J Ethnopharmacol, 2005; 96: 139-43.
16. Geetha M, Shankar MB, Mehta RS, Saluja AK. Antifertility of *Artabotrys odoratissimus* Roxb and *Courouptia guianensis* Aubl. J Nat Rem, 2005; 5 (2): 121- 125.
17. Ghasi S, Nwobodo E, Ofili JO. Hypocholesterolemic effects of crude extract of leaf of *Moringa oleifera* Lam in high-fat diet fed Wistar rats. J Ethnopharmacol. 2000; 69: 21–25.
18. Gupta RS and Sharma R. A review on medicinal plants exhibited antifertility activity in males. Natural Product Radiance, **2006**, 5 (5), 389-410.
19. Kamal R, Gupta RS, Lohiya NK. Plants for male fertility regulation. Phytother Res, 2003; 17: 579- 590.
20. Khanna U, Garg SK, Vohra SB, Walia HB, Choudhary RR. Antifertility screening of plants. II. Effect of six indigenous plants on early pregnancy in albino rats. Indian J Med Res, 1969; 57: 237- 244.
21. Koneri R, Balaraman R, Saraswati CD. Antiovulatory and abortifacient potential of the ethanolic extract of root of *Mormordica cymbalaria* Fenzl in rats. Indian J Pharmacol, 2006; 38 (2): 111- 4.
22. Kosif R, Gulhan A, Oztekin A. Microscopic examination of placenta of rats prenatally exposed to *Aloe barbadensis*: A preliminary study, Int J Morphol, 2008; 2: 275- 280.
23. Lalas S, Tsaknis J. Extraction and identification of natural antioxidants from the stem bark of *Moringa oleifera* tree variety of Malawi. J Am Oil Chem Soc, 2002; 79: 677–683.
24. Long JA, Evans HM. Determination of estrous cycle phases of rats. Brazilian J Biol, 1952; 62: 85-89.
25. Madhavi K, Saraswati VS. In vivo toxicological evaluation of *Chlorpyrifos* pesticide on female albino mice. Therapeutic effects of *Curcuma longa*. Int J Pharmaceutical Sci Res, 2011; 2 (2): 439- 447.
26. Mahajan BK. Methods in Biostatistics for Medical and Research Worker. 6th ed. New Delhi: JAYPEE Brothers Publication, 1997: 398- 410.
27. Makonnen E, Hunde A, Damecha G. Hypoglycaemic effect of *Moringa stenopetala* aqueous extract in rabbits. Phytother Res, 1997; 11: 147–148.
28. Morton JF. The horseradish tree, *Moringa pterigosperma* (Moringaceae). A boon to arid lands. Econ Bot, 1991; 45: 318–333.

29. Mughal MH, Ali G, Srivastava PS, Iqbal M. Improvement of drumstick (*Moringa pterygosperma* Gaertn) – a unique source of food and medicine through tissue culture. Hamdard Med, 1999; 42: 37–42.
30. Nath D and Sethi N. Commonly used Indian abortifacient plants with special reference to their teratologic effect in rats. J Ethnopharmacol, 1992; 36 (2): 147- 154.
31. OECD. Guidance for testing of chemicals, Acute Oral Toxicity- Acute Toxic Class Method, 2001: 423.
32. Oyesola TO, Oyesola OA, Okoye CS. Effects of aqueous of *Aspilia africana* on reproductive function of female wistar rats. Pak J Biol Sci, 2010; 13 (3): 126- 131.
33. Padmarao P, Acharya BM, Dennis TJ. Pharmacognostic study on stembark of *Moringa oleifera* Lam. Bulletin of Medico-Ethno-Botanical Res, 1996 17: 141–151.
34. Prakash AO and Mathur R. Screening of Indian plants for antifertility activity. Indian J Exp Biol, 1976; 14: 623.
35. Reynolds JL. Issues raised by medical abortions. Can Med Assoc J, 1996; 155(1): 19.
36. Schneidereit M. Study of fetal organ growth in wistar rats from day 17 to 21. Laboratory Animals 1985; 19: 240- 244.
37. Singh SP. Fertility control of female through *Sesbani sesbian* seeds. The J Res Edu Indian Med, 1990; 9: 27- 32.
38. Thimmaiah SR. Standard methods of biochemical analysis. Kalyani Press, New Delhi, Edition 2, 2004: 247- 340.
39. Vervest HAM, Haspels AA. Preliminary results with antiprogestational compounds RIU 486 (milepristone) for interruption of early pregnancy. Fertil Steril, 1985, 44, 627.
40. Wikhe M, Zade V, Dabadkar D, Patil U. Evaluation of the abortifacient and estrogenic activity of *Cicer arietinum* leaves on female albino rat. J Bioinnovations, 2013; 2 (3): 105- 113.