

## ORIGINAL ARTICLE

# DETECTION OF HUMAN PAPILLOMAVIRUS USING IN SITU HYBRIDIZATION TECHNIQUE IN VULVO-VAGINAL WARTS

M.A. Siti-Aishah, I. Isahak\*, D. Sabil, F. Sahlan\*, H. Md. Tahir\*\*, A.A. Yahya\*\*

Departments of Pathology

\*Medical Microbiology & Immunology and \*\* Obstetrics & Gynaecology

Faculty of Medicine, Universiti Kebangsaan Malaysia, Bandar Tun Razak

56000 Kuala Lumpur, Malaysia

Human papillomavirus (HPV) is the commonest sexually transmitted viral infection and one of its manifestations is genital warts or condyloma acuminata. Eight cases of vulvo-vaginal warts were diagnosed between January 1992 and December 1993. There were 4 Malays, 2 Chinese and 2 Indians. The patients' age ranged from 22 to 43 years (mean 27.9 years). Formalin-fixed, paraffin-embedded tissues were studied by histology and in situ hybridization using biotinylated probes to detect the HPV deoxyribonucleic acid (DNA) of types 6, 11, 16, 18, 31 and 33. All vulvar and vaginal lesions showed typical histopathological features of condylomatous changes. HPV 6 and HPV 11 were detected in 100% (8/8) and 87.5% (7/8) of all cases, respectively. HPVs 16, 18, 31 and 33 were not found. The positive cells were mainly in the upper layers of the squamous epithelium. The hybridization data indicated that the HPV found in this study one of the same types as found in other studies.

*Key words : Human papillomavirus, warts, vulvo-vagina, in situ hybridization*

## Introduction

Human papillomavirus (HPV) is the commonest sexually transmitted viral infection in the United Kingdom and United States (1-2). Clinically evident cases represent only a small portion of the infected population, with many people having subclinical or latent infection.

There are now at least 80 known human papillomavirus (HPV) types, of which 22 infect the anogenital tract where they are associated with benign condylomas, dysplasia and carcinomas (3). Low oncogenic risk HPVs, such as types 6, 11, 42, 43 and 44 are associated with benign condylomas and low grade dysplasias. DNA hybridization is required to obtain definitive evidence of HPV infection whereas in situ hybridization (ISH) allows simultaneous identification, localization of HPV infected cells and evaluation of tissue morphology in tissue sections and cell cultures (4).

In this report we describe the results of ISH, using probes for the six common HPV viral types,

on condylomata acuminata specimens taken from 8 patients.

## Materials and methods

Tissue samples were obtained from eight patients who attended the Gynaecology Clinic, Universiti Kebangsaan Malaysia from January 1992 to December 1993. All patients were clinically diagnosed for genital warts or condylomata acuminata which were found in the vulvar and vaginal regions. There were no warts seen in the cervical region. The tissues were fixed in 10% buffered formalin, processed for paraffin embedding by routine procedures and stained with haematoxylin and eosin (H and E).

## In situ hybridization

Probes for human papillomavirus DNA were commercially obtained from Dako (USA). The probes were biotinylated, type-specific double-

stranded DNA. The nick-translated probes were prepared from sub-genomic clones of HPV DNAs that were cloned into plasmid vectors. The type-specific probes used were for HPV 6, 11, 16, 18, 31 and 33. Eight sections from each specimen were used : one for each probe and two controls. The negative control probe was prepared from pUC18 plasmid DNA. Specimens from confirmed positive cases were included with each batch of slides as positive controls.

Sections from formalin-fixed tissue blocks were cut at 3-5  $\mu\text{m}$  and mounted on slides coated with triethoxyamino-alkylsilane (Dako® silanized slides). The sections were air dried and kept overnight at 37°C and then incubated in a 60°C oven for 30 minutes (min) to enhance adherence of the cells to the slide. The sections were then dewaxed by two changes of xylenes, for 5 minutes each and immersed twice in 100% alcohol, followed by three changes of 95% alcohol, for one minute each time. The sections were digested for 10 minutes in prewarmed (37°C) pepsin/HCL (0.8% pepsin, 0.2 N HCL) and stopped by washing in two changes of distilled water for 5 minutes.

An HPV tissue hybridization kit (DAKO® in situ hybridization detection system, Dako, Carpinteria, CA, USA), with specific in situ HPV DNA probes was used in this study. The kit was used according to the manufacturer's instructions with minor modifications. A drop of biotinylated probe reagent in hybridization solution was applied to the tissue section and covered with a coverslip. The slides were then put on a flat heating block that had

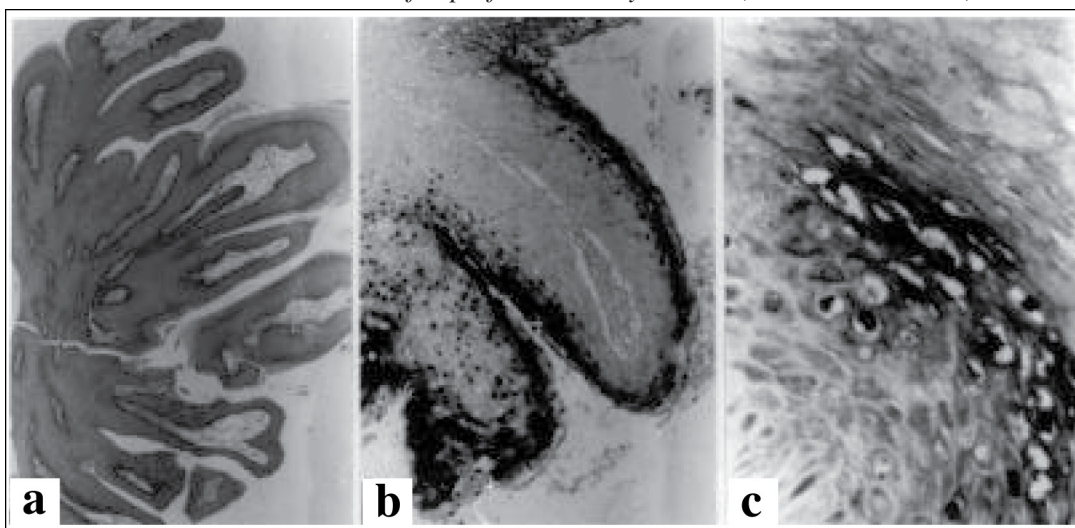
been pre-warmed to 92°C and incubated for 5 minutes. The slides were transferred from the heating block to a pre-warmed humid chamber and hybridized overnight at 37°C. Thereafter the slides were rinsed in Tris-buffered Saline (TBS) solution (0.05M Tris-HCL, 150 mM NaCl, pH 7.6) to remove the coverslips, and then washed once in the buffer for 5 minutes at 37°C. The slides were immersed in the pre-warmed stringent wash solution, incubated in 5 ml of the stringent wash concentrate SCC = 75mM sodium citrate, 750mM sodium chloride, pH 7.6) into 245 ml of distilled water at 48°C for 30 minutes and there after immersed in TBS solution for one minute.

Streptavidin-AP (Alkaline Phosphatase) reagent was applied to each section for 20 minutes at room temperature and was then immersed in TBS solution for 5 minutes. A substrate solution [5-bromo-4-chloro-3-indolylphosphate (BCIP)] and a chromogen [Nitro Blue Tetrazolium (NBT)] were applied to the slides which were then incubated in the dark for 1 hour. These slides were subsequently rinsed in distilled water for 5 minutes.

The slides were counterstained with Nuclear Fast Red for 2 minutes, rinsed in distilled water and mounted in aqueous mounting media. Sections were examined microscopically to allow for morphological examination and visualization of target DNA.

Positive reactions for hybridization were shown as blackish purple stain mainly in the nuclei of infected cells containing target DNA.

*Figure 1: Tissue specimen from Case 4 of vulvar condyloma showing papillomatosis (a, x20). Cells containing HPV 6 DNA by in situ hybridization, indicated by the dark-stained nuclei of superficial koilocytic cells (b, x40 and c, x400).*



## Results

Clinical data are summarized in Table I. The ages ranged from 22 to 43 years (mean 27.9 years). In five cases warts were found in the vulva, 2 in both vulva and vaginal regions and 1 in the vagina.

Of the 8 cases only three cases had complete follow-up data. Results of cases with completed data are as follows:

Case 4) A 24 year old Indian lady had an incomplete abortion where curettage was done. Diathermy excision of the viral warts was done later. No warty lesions were seen in the next follow-up.

Case 5) A 23 year old Malay lady had extensive vulva and vaginal warts. She was treated with medical therapy.

Case 8) A 43 year old Chinese lady was a post renal transplant patient and she was on immunosuppressant medication. Laser ablation was done on the warts but the lesions still remained on follow-up.

Typical condylomata acuminata characterized by papillomatosis (Figure 1a), hyperkeratosis, acanthosis, parakeratosis and viral cytopathic effect

consisting of nuclear degenerations and perinuclear halos (koilocytosis) in the mature regions of the epithelium were seen in all the cases.

The results of in situ hybridization are shown in Table I. The staining pattern with specific biotinylated DNA was observed as dense and homogenous, blackish purple nuclear stain, predominantly located in the superficial squamous epithelial cells, corresponding to koilocytotic cells that are a recognized morphological expression of HPV infection. The condylomata showed many nuclei reacting positively for HPV 6 and/or 11 (Figure 1 b & c).

## Discussion

Genital warts or condyloma acuminata, one of the manifestations of genital HPV infections, are contagious and usually sexually transmitted. Condylomas range in frequency from 1 to nearly 50 percent in various populations (5-6). They are usually multiple lesions and may involve the vulva, vagina, cervix, urethra, anal and perianal skin (8). Age incidence peaks between 16 to 25 years, as does

Table 1: Clinical, histological data and hybridization results in patients with vulvo-vaginal warts

Case	Age (Years)	Race	Site	Clinical history	HPV 6	11	16	18	31	33
1	28	Chinese	Vulva	Mass	+	+	-	-	-	-
2	22	Malay	Vulva	Swelling	+	+	-	-	-	-
3	23	Malay	Vulva	Pregnancy with multiple lesions	+	+	-	-	-	-
4	24	India	Vulva	Incomplete abortion & multiple lesions	+	+	-	-	-	-
5	23	Malay	Vulva & vagina	Multiple lesions	+	+	-	-	-	-
6	28	Malay	Vulva & vagina	Multiple lesions	+	+	-	-	-	-
7	32	India	Vulva	Pregnancy with multiple lesions	+	-	-	-	-	-
8	43	Chinese	Vagina	Postrenal transplant & multiple lesions	+	+	-	-	-	-

that of other sexually transmitted disease (7). In our study of 8 patients, the mean age was 27.9 years. Vaginal condylomas can be detected by careful examination in as many as one third of women who have vulvar condylomas (9). Vaginal condylomas are usually multiple and similar lesions will be present on the cervix in about 20 percent of patients. Uncommonly, the vagina may be involved throughout its entire length. Usually, the distribution will be patchy, with the upper and lower thirds of the vagina being affected most frequently. Our patients had lesions confined to the vulva and vagina by clinical examination and 6 of them had multiple lesions. The cervical region was not involved.

Condyloma acuminata are commonly associated with vaginitis, pregnancy, diabetes mellitus, oral contraception use, poor perineal hygiene, immunosuppression and sexual activity with multiple partners (10). In pregnant and immunosuppressed women, vaginal lesions may become exuberant. At the time of presentation, two of our patients were pregnant (Cases 3 and 7), one had a renal transplant (case 8) and another had an incomplete abortion (case 4).

Condylomas are typically verrucous, papillary or sessile, but may appear as red, granular areas. Vaginal condylomas are similar in their gross and microscopic appearance to condylomas arising on the ectocervix and vulva. All vulvar and vaginal lesions showed typical histopathological features of classical condylomata. They are characterized by marked acanthosis with hyperplasia of the prickle cell layer, parakeratosis, and at times, underlying chronic inflammation (11). They show a tendency toward upward growth and contain infective koilocytotic cells in the more superficial layer (12). Our cases showed similar findings.

Several types of HPV DNA tests are available, including Southern blots, dot blot, in situ hybridization (ISH), polymerase chain reaction and solution hybridization (Hybrid Capture assay) (13). HPV DNA detection assays are not routinely used in screening patients, in part because the clinical relevance of asymptomatic infection is unclear. Nevertheless, these tests may be beneficial in confirming differential diagnoses and in providing prognostic information, particularly with respect to the type of HPV involved (13-14). In situ hybridization assays when performed on histologic material that has been fixed to specially treated glass slides has the advantage of revealing the location of specific HPV-infected cells on tissue regions (13). The viral distribution pattern in our tissues was in

agreement with other reports: virus presence was often detected in the deep layers, and progressively stronger signals were seen in the spinous, granular and superficial layers in accordance with the suggested relationship between viral replication and squamous cell differentiation (15-16).

Using molecular hybridization with labeled HPV DNA, typical exophytic vulvar and vaginal condylomata acuminata positive for HPV 6 and HPV 11 have been described in approximately 80 to 90% of cases (17). Previous reports suggested that HPV 6 and HPV 11 have the potency to induce the specific pathological changes, condylomata, in any region of the female lower genital tract and frequently showing viral cytopathic effect (16,18). Other studies have shown that HPV 11 occurred in approximately one-fourth of genital warts, in cervical dysplasias and some cervical carcinoma (19). In a study on 9 Chinese patients with genital condylomata acuminata, HPV DNA was positive for HPV 6 in 66.7% (6/9), HPV 11 in 22.5% (2/9) and HPV 18 in 11.1% (1/9) of cases (20). Our studies showed HPV 6 was found in 100% (8/8) and HPV 11 in 87.5% (7/8) of cases. HPVs 16, 18, 31 and 33 were not observed. Our only 2 Chinese patients were positive for both HPV 6 and HPV 11.

The results of our limited study confirmed previous observations on the association of HPV 6 and HPV 11 on vulvo-vaginal warts (17-20).

## Acknowledgement

The authors thanked Encik Rosli Nasir of Hospital Universiti Kebangsaan Malaysia for preparing the photographs.

This study was supported by the Ministry of Science, Technology and Environment (Grant No.03-07-03-075).

## Correspondence :

Dr. M.A. Siti-Aishah,  
Department of Pathology,  
Faculty of Medicine,  
Universiti Kebangsaan Malaysia,  
Bandar Tun Razak,  
56000 Kuala Lumpur, Malaysia.

## References

1. Sonnex, C. Human papillomavirus infection with particular reference to genital disease. *J Clin Pathol.* 1998; **51**:643-48.

2. Stone, K.M. Epidemiologic aspects of genital HPV infection. *Clin Obstet. Gynecol.* 1989; **32**:112-16.
3. Van den Brule, A.J.C., Sniders, P.J.F., Meijer, C.J.L.M., and Walboomers, J.M.M. PCR-based detection of genital HPV genotypes, an update and future perspectives. *Papillomavirus report*.1993; **4**:95-99.
4. Syrjanen, S.M., von Krogh, G., and Syrjanen, K.J. Detection of human papillomavirus DNA in anogenital condylomata in men using in situ DNA hybridization applied to paraffin sections. *Genitourin Med.* 1987; **63**:32-39.
5. Moore, G.E., Norton, L.W., Meiselbauhg, D.M. Condyloma as a new epidemic. *Archives of Surgery.* 1987;**113**:630-35.
6. Kurman, R.J., Norris, H.J., Wilkinson, E. Tumors of the vulva. In: *Tumors of the cervix, vagina and vulva. Atlas of tumor pathology.* Armed Forces Institute of Pathology. 3<sup>rd</sup> Series. Fascicle 4. Washington D.C. 1992:180-82.
7. Communicable Disease Surveillance Centre. Sexually transmitted disease surveillance in Britain 1984. *Br Med J.* 1986; **293**:942-43.
8. Lynch, P.J. Condylomata acuminatas (anogenital warts). *Clin Obstet. Gynecol.* 1985;**28**:1421-5.
9. Roy, M., Meisels, A., Fortier, M., Morin, C., Casas-Cordero, M., and Robitaille, C.G. Vaginal condylomata: A human papilloma virus infection. *Clin Obstet Gynecol.* 1981;**24**:461-470.
10. Oriel, J.D. Natural history of genital warts. *Br J Vener.* 1971; **47**:1-13.
11. Butler, E.B., and Stanbridge, C.M. Condylomatous lesions of the lower female genital tract. *Clin Obstet Gynecol.* 1984; **11**:171-87.
12. Woodruff, J.D., Braun, L., Cavalieri, R., Gupta, P., Pass, F. and Shah, K.V. Immunological identification of papillomavirus antigen in paraffin-processed condyloma tissues from the female genital tract. *Obstet Gynecol.* 1980;**56**:727-32.
13. Reid, R., and Lorincz, A.T. Human papillomavirus tests. *Bailliere's Clin Obstet Gynaecol.* 1995;**9**:65-103.
14. Johnson, K. Canadian Task Force on the Periodic Health Examination. Periodic health examination, 1995 update: 1. Screening for human papillomavirus infection in asymptomatic women. *Can Med Assoc J.* 1995;**152**:483-93.
15. Syrjanen, S.M., Partenan, P., Mantyarvi, R., and Syrjanen, K.J. Sensitivity of in situ hybridization techniques using biotin and <sup>35</sup>S-labelled human papillomavirus (HPV) DNA probes. *J Virol Methods.* 1988;**19**:225-38.
16. Garuti, G., Boselli, F., Genazzani, A.R., Silvestri, S., and Ratti, G. Detection and typing of human papillomavirus in histologic specimens by in situ hybridization with biotinylated DNA probes. *Am J Clin Pathol.* 1989;**92** :604-12.
17. Schneider, A., Sawada, E., Gissman, L., Shah, K. Human papillomaviruses in women with a history of abnormal Papanicolaou smears and in their male partners. *Obstet Gynecol.* 1987; **69**:554-562.
18. Sugas, M., Moriyama, S., and Matsukura, T. Human papillomavirus in exophytic condylomatous lesions on different female genital regions. *J Med Virol.* 1991; **3**: 1-6.
19. Gissman, L., de Villers, E.M., and zur Hansen, H. Analysis of human warts (condyloma acuminata) & other genital tumors for human papillomavirus type 6 DNA. *Int J Cancer.* 1982; **29**: 143-48.
20. Chang, F., Syrjanen, S., Shen ,Q., Ji, H., and Syrjanen K. Detection of human papillomavirus (HPV) in genital warts and carcinomas by DNA in situ hybridization in Chinese patients. *Cytopathology.* 1990; **1** : 97-103.