

The Clinical Significance of Ulnar Artery Morphology in Artificial Arterial-Venous Fistula for Hemodialysis

Waseem Bader AL TALALWAH¹, Dereje Regassa GETACHEW²

Submitted: 14 Oct 2014

Accepted: 16 Feb 2014

¹ Department of Basic Medical Sciences Hospital King, Abdullah International Medical Research Center/King Saud bin Abdulaziz University for Health Sciences, College of Medicine, – NGH A Riyadh, P.O. Box 3660, 11481 Riyadh

² Department of Anatomy, Hawassa University College of Medicine and Health Sciences, School of Medicine, post code 1560, Awassa, Ethiopia

Abstract

Background: The ulnar artery is a terminal branch of the brachial artery. The aim of this study is to provide comprehensive data concerning the morphology of the ulnar artery, with clinical implications for surgeons.

Methods: The current study includes the dissection of 68 upper limb specimens. It investigates the characteristics of the ulnar artery such as the internal diameter, external diameter, wall thickness, and distance of the ulnar artery origin.

Results: In this study, the ulnar artery arose distal to the superior margin of the head of the radius in 82.65% of cases. The angle degree of the ulnar artery with respect to the brachial artery ranges from 8° to 30°. The internal and external diameters of the ulnar artery were found to decrease gradually from proximal to distal in both genders. The external and internal diameters of the ulnar artery are greater in males than in females. In all cases, the external and internal diameters and the thickness of the ulnar artery at three levels were found to be greater in the right ulnar artery than the left.

Conclusion: The right ulnar artery may be the appropriate choice for artificial arterial-venous fistula for haemodialysis. Due to its wide diameter, the proximal part of the radial artery is a suitable site for the artificial arterial-venous fistula immediately below the origin prior to its profound course. Therefore, it is an easy access for artificial arterial-venous fistula for surgeons. The radiologists must alert the surgeons for surgical modification in the case of high brachial bifurcation.

Keywords: axillary artery, brachial artery, ulnar artery, cadaver, dissection, haemodialysis, sex factor, human, ulnar fistula

Introduction

The brachial artery is the continuation of the axillary artery at the inferior border of the teres major, which passes distally and laterally, lying medial to the biceps brachii and anterior to the coracobrachialis and brachialis. In the cubital fossa, the brachial artery lies deep with respect to the bicipital aponeurosis. At the end, it bifurcates into the radial and ulnar arteries. As the brachial artery enters the forearm from the arm through the cubital fossa, it divides into its two terminal branches, the radial and the ulnar arteries, at the apex of this fossa. The ulnar artery usually arises at the level of the radial head in the cubital fossa but may arise more proximally. The ulnar artery is larger than the radial artery and begins slightly below the bend of the elbow in the cubital fossa, passing obliquely downward to reach the

medial side of the forearm at a point midway between the elbow and wrist. It is the main blood supply on the medial aspect of the forearm. It arises from the brachial artery and leaves the cubital fossa by passing deep with respect to the pronator teres and passes through the forearm between the flexor carpi ulnaris and the flexor digitorum profundus. The ulnar artery terminates in the superficial palmar arch, which joins with the superficial branch of the radial artery. It is palpable on the anterior and medial aspect of the wrist, but in the distal forearm, it remains covered under the anterolateral lip of the flexor carpi ulnaris tendon and therefore is not easily palpable. Then, it runs along the ulnar border to the wrist to leave the forearm entering the hand by crossing the transverse carpal ligament on the

radial side of pisiform and superficial to the flexor retinaculum, then immediately divides into two branches that contribute to the formation of the superficial and deep palmar arches (1). The aim of the current study is to measure the internal and external diameter of the ulnar artery as well as its thickness to provide sufficient anatomical information to improve its clinical application in creating artificial arteriovenous (AV) fistulas in patients with end stage renal disease (ESRD) if radial or brachial arteries are unavailable. Therefore, it is important to know the thickness, diameter and variability of the ulnar artery in the upper limb for clinicians and anatomists. Due to variable origins and diameters of the ulnar artery, frequent vascular injury may occur during surgery or invasive vascular procedures.

Materials and Methods

This study involves the dissection of 34 cadavers (14 female and 20 male) with a total of 68 upper limbs (34 right, 34 left) and an age range of 37–96 years. In each dissection, the ulnar artery was exposed. The origin of the ulnar artery (Figure 1) and its internal and external diameters were examined using a vernier calliper, ruler, and protractor. For the ulnar artery, the measurements of the means and associated standard deviations (mm) of the external and internal diameters and thickness of the ulnar artery at its origin, at the level of the common interosseous artery origin and at the wrist in males and females as well as in entire cases were taken. The angle of origin of the ulnar artery from the brachial artery was measured in the cubital fossa along with its internal and external diameter. An imaginary line drawn along the brachial artery was used as a reference point to measure the angles. The angle of the radial artery was measured first followed

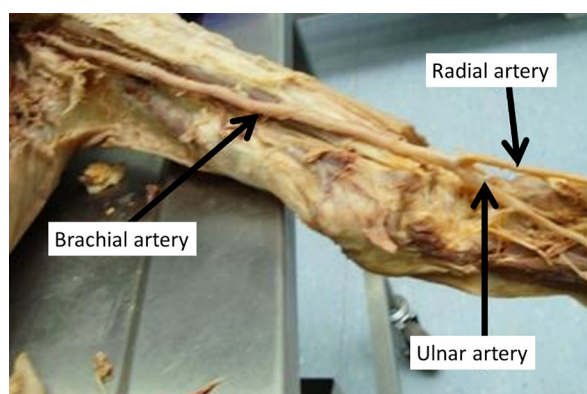


Figure 1: The ulnar artery origin.

by the angle of the ulnar artery. In the forearm, the internal and external diameters of the ulnar artery (proximal, middle, and distal parts) were also measured.

The data were collected from both limbs in 14 females and 20 males: the mean male and female ages were 81 ± 7.2 and 75.9 ± 16.3 respectively. The combined mean age is 78.9 with a standard deviation of 11.9 years. The range of ages of all cadavers was 37 to 96 years. This study includes 68 dissected upper limbs to investigate the ulnar artery origin, its internal diameter, external diameter, wall thickness and distance of ulnar artery origin. The data were collected and the mean and standard deviation calculated. *t* tests were performed to assess differences in arterial diameter between females and males and right and left sides, as well as along the length of the ulnar artery.

Result

In males, the mean and standard deviation and the range of origin angle of the ulnar artery on the left side were found to be 19.52 mm, 5.51 mm, and 11° – 30° , respectively. The mean and standard deviation and the range of origin angle of the ulnar artery on the right side were found to be 19.9 mm, 5.57, mm and 9° – 31° , respectively. In females, the mean and standard deviation and the range of origin angle of ulnar artery of the left side were found to be 17.38 mm, 6.02 mm, and 8° – 30° , respectively. The mean and standard deviation and the range of origin angle of the ulnar artery on the right side were found to be 18.6 mm, 5.22 mm, and 11° – 30° , respectively. In the total cases, the mean and standard deviation and the range of bifurcation angles of the ulnar artery of the left side were found to be 18.64 mm, 5.63 mm, and 8° – 30° , respectively. The mean and standard deviation and the range of bifurcation angles of the ulnar artery on the right side were found to be 19.36 mm, 5.5 mm, and 9° – 31° , respectively (Table 1 and 2).

The internal and external diameter of the ulnar artery at its origin, at the level of the common interosseous artery origin and at the wrist were found to decrease gradually from proximal to distal in both females and males (Table 3). In males, the means and associated standard deviations (mm) of the external and internal diameters at the origin and at the level of the common interosseous artery origin of the left ulnar artery are greater than on the right side; however, the right ulnar artery is thicker than the left ulnar artery at the level of the wrist. In females,

Table 1: The means and the standard deviations

Ulnar artery	Side	Mean (mm)	Standard Deviation (mm)
Male	Left	19.52	5.51
	Right	19.90	5.75
Female	Left	17.38	6.02
	Right	18.60	5.22
Total	Left	18.64	5.63
	Right	19.36	5.50

Paired *t* test: *t* value = 0.5334, *df* = 66, *P* value = 0.59. The right and the left samples are not significantly different.

Table 2: The range of origin angles of ulnar artery in male and female as well as total cases

Ulnar artery		Side	Origin of ulnar artery proximal to superior margin of the head of the radius ^a	Origin of ulnar artery distal to superior margin of the head of the radius ^b	Range of angle degree of ulnar artery from brachial artery
Sex ^c	Male	Left ^d	0% (0 out of 20)	100% (20 out of 20)	11°–30°
		Right ^d	25% (5 out of 20)	75%	9°–31°
	Female	Left ^d	0% (0 out of 20)	100% (14 out of 14)	8°–30°
		Right ^d	0% (0 out of 20)	100% (14 out of 14)	11°–30°
Total		Left ^d	0% (0 out of 34)	100% (34 out of 34)	8°–30°
		Right ^d	14.7% (5 out of 34)	85.3% (5 out of 34)	9°–31°

^aOrigin of ulnar artery is proximal to superior margin of the head of the radius in 7.35%.

^bOrigin of ulnar artery is distal to superior margin of the head of the radius in 82.65%.

The data is based on paired *t* test.

^cSignificantly (*P* < 0.05) larger than corresponding female value.

^dSignificantly (*P* < 0.05) larger than corresponding right side value.

the means and associated standard deviations (mm) of the external and internal diameters at its origin and at the level of the common interosseous artery origin of the right ulnar artery are greater than for the left ulnar artery; however, the means and associated standard deviations (mm) of the external diameter and thickness of the left ulnar artery are greater than for the right ulnar artery at the level of the wrist. Furthermore, the means and associated standard deviations (mm) of the internal diameter of the right ulnar artery are greater than for the left ulnar artery.

According to gender comparison in the left or right side, the study shows that the means and associated standard deviations (mm) of the external and internal diameters of the ulnar artery at its origin, at the level of the common interosseous artery origin and at the wrist in males are all greater than in females. Further, the mean of the thickness of the left or right ulnar artery at the level of its origin and at the wrist were found to be greater in males than females except in that

the thickness of the right ulnar artery in females is greater than in males at the level of the common interosseous artery origin. In all cases considered together, the means and associated standard deviations (mm) of the external and internal diameters and thickness of the ulnar artery at its origin, at the level of the common interosseous artery origin and at the wrist were found to be greater for the right ulnar artery than the left one (Table 3). In addition, there is a significance (*P* < 0.05) difference between male and female values, with males being larger, as well as between right and left side thickness at certain levels.

Discussion

Vascular upper limb variability is due to either growth or involution of the buds plexus during embryonic development. (2–7). As a result, any defects in the embryonic development of the vascular plexus of the upper limb buds may produce assorted variations in the arterial origins

Table 3: Means and associated standard deviations (mm) of the external and internal diameters and thickness of the ulnar artery at its origin, at the level of the common interosseous (CI) and at the wrist in males and females as well as in total cases

Ulnar artery	Side	Mean (SD)		
		External diameter ^c	Internal diameter ^d	Thickness ^e
Male	Left			
	Origin	4.82 (0.77)	4.27 (0.66) ^a	0.28 (0.06) ^b
	CI	3.21 (0.70) ^a	3.00 (0.49) ^a	0.10 (0.11)
	Wrist	3.02 (0.74)	2.64 (0.54) ^a	0.19 (0.10)
	Right			
	Origin	4.81 (0.78) ^a	4.36 (0.60) ^a	0.22 (0.09)
	CI	3.18 (0.66)	2.95 (0.47)	0.12 (0.09)
	Wrist	3.07 (0.66) ^a	2.65 (0.43) ^a	0.21 (0.11) ^a
Female	Left			
	Origin	3.97 (0.79)	3.59 (0.64)	0.19 (0.08)
	CI	2.77 (0.60)	2.59 (0.52)	0.09 (0.04)
	Wrist	2.64 (0.93)	2.19 (0.60)	0.22 (0.16) ^b
	Right			
	Origin	4.03 (0.86)	3.61 (0.77)	0.21 (0.04)
	CI	2.96 (0.70)	2.70 (0.49)	0.13 (0.11)
	Wrist	2.43 (0.58)	2.31 (0.50)	0.06 (0.04)
Total	Left			
	Origin	4.47 (0.88)	3.99 (0.73)	0.24 (0.08)
	CI	3.03 (0.68)	2.83 (0.53)	0.10 (0.08)
	Wrist	2.86 (0.83)	2.46 (0.60)	0.20 (0.12)
	Right			
	Origin	4.49 (0.89)	4.05 (0.76)	0.22 (0.06)
	CI	3.09 (0.68)	2.84 (0.49)	0.12 (0.09)
	Wrist	2.80 (0.69)	2.51 (0.49)	0.15 (0.10)

^aSignificantly ($P < 0.05$) larger than corresponding female value.^bSignificantly ($P < 0.05$) larger than corresponding right side value.^cExternal diameter : t value = -0.0535 , $df = 66$, P value = 0.95 . Therefore, the external diameter of the left and right samples is not significantly different.^dInternal diameter: t value = -0.2747 , $df = 66$, P value = 0.7847 . Therefore, the internal diameter of the left and right samples is not significantly different.^eThickness of left and right side: t value = 0.9685 , $df = 66$, P value = 0.34 . Therefore, the left and right sample thickness is not significantly different.

and courses of the major upper limb vessels. (8). The variability of the vascular upper limb has been described in several research studies (3,7,9,10) as ranging from 9–18.5% (11). In a recent study, it was found to exhibit a high prevalence, reaching 34.7% (12). Studying the vascular variations of the upper limb provides clinical significance in several respects (6,13), such as modified surgical interference in the case of high bifurcation of the brachial artery when performing artificial

arteriovenous fistula. Consequently, it is important for clinicians and anatomists to understand the thickness, diameter, and variability of the ulnar artery in the upper limb because a number of surgical and invasive procedures are performed in the cubital region (14). Such understanding may help to minimise iatrogenic faults.

The ulnar artery usually arises at the level of the neck of the radius (1) in 21.7% of cases, but it may arise either proximal or distal to this

level in 11.7% or 6%, respectively (15). In series of studies, the ulnar artery was found to arise proximal to the intercondylar line (3,7,16–22) in 10% (15) or in 12.3% of cases (23). However, the previous studies have no details regarding the origin of the ulnar artery proximal and distal to the superior margin of the head of the radius according to gender or side as well as its range of angle degree with respect to the brachial artery. In this study, the ulnar artery usually arose distal to the superior margin of the head of the radius in 82.65% of cases, ranging from 2.33 to 30 mm. It infrequently arose proximal to the superior margin of the head of the radius in 7.35%. It was found to be more frequent in males and on the left side only. In this study, the angle of bifurcation of the ulnar artery on the left and right side ranges between 8°–30° and 9°–31°, respectively.

In a series of studies, the diameter ulnar artery was found to average 4.3 mm at its origin (23–29). The means of the internal diameter of right and left ulnar artery were found to be 2.4 mm and 2.3 mm, respectively (30), at the origin and 2.5 mm and 2.4 mm at the wrist (25). Generally, the internal diameter of the ulnar artery was found to be 3.6 mm at the elbow region (23). The previous studies have no complete evaluation of the internal diameter of the ulnar artery from proximal to distal sites. In this study, the internal diameters of the left ulnar artery were found to be 3.99 mm, 2.83 mm and 2.46 mm, whereas the internal diameters of the right ulnar artery were found to be 4.05 mm, 2.84 mm, and 2.51 mm at the origin, the common interosseous artery origin and at the wrist levels, respectively. Therefore, the internal diameter of the ulnar artery is found to be large at its origin and small at wrist. Further, the right ulnar artery is larger than the left ulnar artery in all measurements. This result indicates a strong agreement of this current study with the previous studies.

Furthermore, the external diameter of the ulnar artery ranges from 4.5 mm to 6.5 mm proximally and 2.5 mm to 4 mm distally according to studies performed by Claassen et al. (27). In this study, the external diameter of the left ulnar artery is 4.47 mm, 3.03 mm, and 2.86 mm, whereas the external diameter of the right ulnar artery is 4.49 mm, 3.09 mm, and 2.80 mm at its origin, the common interosseous artery origin and at the wrist levels (Table 3). Therefore, the external diameter ulnar artery gradually decreases in size from proximal to distal in all cases, supporting the studies by Claassen et al. (27). Furthermore, the external diameter of right ulnar artery is larger than the left ulnar artery at all levels.

According to series of studies (23,31,32), the success rate of artificial arteriovenous fistula increases when the internal diameter of the artery is 1.6 mm or broader. Consequently, the ulnar artery is an appropriate choice of artificial arteriovenous fistula for patients in the case of short and high bifurcation of the radial artery course.

Conclusion

Understanding the anatomical morphological feature of the ulnar artery is key to minimising iatrogenic complications and selecting the correct artery. Due to the size of the ulnar artery, the selection of the right side ulnar artery increases the success rate of artificial arteriovenous fistula in both genders. Further, the female has an increased success rate in previous procedures based on the size of the ulnar artery, which was found to be larger than in males. Therefore, the radiologist should determine the arterial diameter (both internal and external) and the wall thickness using ultrasonography to alert the surgeons, thus improving the artificial arteriovenous fistula for patients who need haemodialysis.

Acknowledgment

We would like to thank Professor Roger William Soames for his support and cooperation to succeed this project. Also, we would like to thank entire employees in Centre for Anatomy and Human Identification who arrange the mandatory facilities for this research as well as King Saud bin Abdulaziz University for Health Sciences.

Conflict of Interest

None.

Funds

None.

Authors' Contributions

Conception and design, analysis and interpretation of the data, drafting of the article, critical revision of the article for the important intellectual content, final approval of the article, provision of study materials or patient, statistical expertise, obtaining of funding, administrative, technical or logistic support and collection and assembly of data: WAT, DRG

Correspondence

Dr Waseem Al-Talalwah
BSc, MD (Gulf University)
MSc, PhD (University Dundee)
Department of Basic Medical Sciences
College of Medicine
King Saud bin Abdulaziz University for Health Sciences
P.O. Box 3660
11481 Riyadh
Tel: +0096611 4295259
Fax: +0096611 42-95276
Email: altalalwahw@ksau-hs.edu.sa

Reference

1. Standring S. *Gray's Anatomy: The Anatomical Basis of Clinical Practice*. 39th ed. London (LDN): Churchill Livingstone; 2004.
2. Singer E. Embryological patterns persisting in the arteries of the arm. *Anat Rec*. 1933;**55**(4):406-413. doi: 10.1002/ar.1090550407.
3. McCormack LJ, Cauldwell, EW, Anson BJ. Brachial and antebrachial arterial patterns; a study of 750 extremities. *Surg Gynecol Obstet*. 1953;**96**(1):43-54.
4. Arey LB. *Developmental Anatomy: Development of the Arteries*. 6th ed. Philadelphia (PA): W.B. Saunders' co; 1957. p. 375-77.
5. Rodriguez-Baeza A, Nebot J, Ferreira B, Reina F, Perez J, Sanudo JR, et al. An anatomical study and ontogenic explanation of 23 cases with variations in the main pattern of the human brachio-antebrachial arteries. *J Anat*. 1995;**187**(Pt 2):473-479.
6. Jurjus AR, Correa-De-Aruaujo R, Bohn RC. Bilateral double axillary artery: embryological basis and clinical implications. *Clin Anat*. 1999;**12**(2):135-140. doi: 10.1002/(SICI)1098-2353.
7. Rodriguez-Niedenfuhr M, Vazquez, T, Nearn L, Ferreira B, Parkin I, Sanudo JR. Variations of the arterial pattern in the upper limb revisited: a morphological and statistical study, with a review of the literature. *J Anat*. 2001;**199**:547-566. doi: 10.1046/j.1469-7580.2001.19950547.
8. Ali SN, Srivastava S. Study of ulnar and radial arteries at wrist level in smokers. *Scand J Plast Reconstr Surg Hand Surg*. 2008;**42**(6):320-324. doi: 10.1080/02844310802299742.
9. Bergman RA, Thompson SA, Afifi AK. *Catalog of Human Anatomical Variation*. Baltimore (BL): Urban Schwarzenberg; 1985.
10. Watanabe M, Takatsuji, K, Sakamoto N, Morita Y, Ito H. Two cases of fusion of the musculocutaneous and median nerves. *Kaibogaku Zasshi*. 1985;**60**(1):1-7.
11. Ciervo A, Kahn M, Pangilian AJ, Dardik H. Absence of the brachial artery: report of a rare human variation and review of upper extremity arterial anomalies. *J Vasc Surg*. 2001;**33**(1):191-194. doi: 10.1067/mva.2001.112212.
12. Vandana R, Suresh NM, Lakshmi PR, Veena P. Variation in course and branching pattern of Brachial artery. *Anatomica Karnataka*. 2012;**6**(3):42-48.
13. Pandey SK, Gangopadhyay AN, Tripathi SK, Shukla VK. Anatomical variations in termination of the axillary artery and its clinical implications. *Med Sci Law*. 2004;**44**(1):61-66.
14. Malcic GJ, Gurunluoglu R, Ozdogmus O, Yalin, Aymelek A. Unique case of trifurcation of the brachial artery: Its clinical significance. *Clinic Anat*. 2002;**15**(3):224-227. doi: 10.1002/ca.10005.
15. Al-Sowayigh MA, Zaki AI, El-Haggagy AA, Abdel Aal IH, Badawoud MH. Anatomical variation of brachial artery bifurcation. *Saudi Med J*. 2013;**34**(9):908-912.
16. Moore KL, Dalley A. *Clinically Orientated Anatomy*. Baltimore (BL): Lippincott Williams and Wilkins; 1999.
17. Celik HH, Germus G, Aldur MM, Ozcelik M. Origin of the radial and ulnar arteries: variation in 81 arteriograms. *Morphologie*. 2001;**85**(269):25-27.
18. Patnaik VVG, Kalsey G, Singla RK. Trifurcation of brachial artery- A case report. *J Anat Soc Ind*. 2001;**50**(2):163-165.
19. Quarraat-ul-Ain, Kauser Y, Raza TA. High division of brachial artery and analogous? Start of radial and ulnar arteries. *Ann King Edward Med Coll*. 2002;**8**(1):30-31.
20. Cherukupalli C, Dwivedi A, Dayal R. High bifurcation of brachial artery with acute arterial insufficiency: a case report. *Vasc Endovascular Surg*. 2008;**41**(6):572-574. doi: 10.1177/1538574407305798.
21. Sathynarayan N, Sunitha P, Shaik MM, Sathyvathi devi P. Brachial artery with high up division with its embryology basis and clinical significance. *IJAV*. 2010;**3**:56-58.
22. Singh H, Gupta N, Bargartra RN, Singh NP. Higher bifurcation of brachial artery with superficial course of radial artery in forearm. *JK Science*. 2010;**12**(1):39-40.
23. Kian K, Shapiro JA, Salman L, Khan RA, Merrill D, Garcia L, et al. High Brachial Artery Bifurcation: Clinical Considerations and Practical Implications for an Arteriovenous Access. *Sem Dialysis*. 2012;**25**(2):244-247. doi: 10.1111/j.1525-139X.2011.00964.x.
24. Saitio S, Hajimethari, Hosekawa G, Tanaka S. Influence of the ratio between Radial Artery inner diameter and sheath outer Diameter on radial artery flow after transradial Coronary intervention. *Cathet Cardiovasc Interven*. 1999;**46**(2):173-178.
25. Riekkinen H V, Karkola KO, Kankainen A. The radial artery is larger than the ulnar. *Ann Thorac Surg*. 2003;**75**(3):882-884.
26. Aptekar E, Dupony P, Chaouch MC, Bussy N, Catarino G. Percutaneous Transulnar Artery approach for diagnostic and Therapeutic Coronary Interventions. *J Inv Card*. 2005;**17**(6):312-317.

27. Claassen, H, schmitt, O, Wree, A. Large patent median arteries and their relation to the superficial palmar arch with respect to history, size consideration and clinic consequences. *Surg Radiol Anat.* 2008; **30(1)**:57–63.
28. Loh YJ, Naka M, Tan WD, Lin CH, Tan YS, Chua YL. Factors influencing radial artery size. *Asian Cardiovasc Thorac Ann.* 2007;**15(4)**:324–326. doi:10.1177/021849230701500412.
29. Jeleu L, Surchev L. Radial artery coursing behind the biceps brachii tendon: Significance for the transradial catheterization and a clinically oriented classification of the radial artery variations. *CVIR.* 2008;**31(5)**:1008–1012. doi: 10.1007/s00270-007-9286-0.
30. Ashraf T, Panhwar Z, Habib S, Memon MA, Shamsi F, Arif J. Size of radial and ulnar artery in local population. *J Pak Med Assoc.* 2010;**60(10)**:817–819.
31. Malovrh M: Non-invasive evaluation of vessels by duplex sonography prior to construction of arteriovenous fistulas for haemodialysis. *Nephrol Dial Transplant.* 1998;**13(1)**:125–129. doi: 10.1093/ndt/13.1.125.
32. Malovrh M: Native arteriovenous fistula: preoperative evaluation. *Am J KidneyDis.* 2002;**39(6)**:1218–1225. doi: http://dx.doi.org/10.1053/ajkd.2002.33394.