

ORIGINAL ARTICLE

NOISE EXPOSURE EFFECT ON TESTICULAR HISTOLOGY, MORPHOLOGY AND ON MALE STEROIDOGENIC HORMONE

Chandralekha G.Swami , Jeganathan Ramanathan*, Charan Jeganath.C**

Department of Anatomy, School of Medical Sciences, Universiti Sains Malaysia, Health Campus
16150 Kubang Kerian, Kelantan, Malaysia.

* Department of Anatomy, Ragas Dental college, Chennai, India. ** Sri Ramachandra medical college
and Research Institute (Deemed university), Chennai, India.

The noise stress, after it passes through the hearing apparatus, not only affects the auditory apparatus but also other body functions. The alterations in the levels of cortical hormone, adrenocorticosterone, nor-epinephrine hormone (which are primarily considered as stress hormones) on follicular stimulating hormone, testosterone, and luteinizing hormone were reported in relation with stress. Male albino rats weighing 200 to 250 grams were exposed to 100 dB of noise for one hour and three hours in acute group and daily one hour exposure for 60 day, and 90 day in chronic group. The serum testosterone levels were measured in these animals. There was significant reduction in serum testosterone levels and this was similar with earlier reports. The tissues were collected for light and confocal microscopic study. 100dB of traffic noise exposure of varying duration had definite permanent effect on testicular histology and morphology and on the male sex hormone. The adaptation mechanism was noticed at the hormonal level only but the structural changes noticed were definite and permanent. The agglutinated dead sperms revealed the possibility of infertility when chronically exposed to noise stress.

Key words : noise stress, spermatogenesis, sex hormone

Submitted-20-02-2004, Accepted-03-12-06

Introduction & Review of Literature

Of all types of environmental pollutants, noise is the most prevalent and insidious natural pollutant which causes deleterious physiological and structural effects. Noise is also partially responsible for reduced reproductivity (1)

Detrimental effect of noise/music on video players on long term effects of noise exposure are well documented as being harmful (2). Abnormalities in reproduction were also reported and there is a significant decrease in pregnancy rate and lethal effect in mice embryos exposed to high frequencies of noise. The teratogenic and embryofetotoxic potential of a broad band of high-frequency (16-42 kHz), high-intensity (110 dB sound pressure level), temporally uniform noise was evaluated in CD-1 mice (3). Noise stress was related

with neuroendocrinological response (4). Most of the studies documented revealed the alterations in the levels of cortical hormone, adrenocorticosterone and nor-epinephrine hormone levels which are primarily considered as stress hormones and also on testosterone, follicular stimulating hormone and luteinizing hormone levels (5). The testosterone response was impaired by water restriction, heat exposure and immobilization exposure. Acute noise stress of 80 dB increased the testosterone level (6). Testosterone production was adversely affected by nutritional factors (7). Glucocorticoid mediation of suppressed testosterone biosynthesis was also seen in male mice exposed to immobilization stress (8). The pituitary-gonadal response to stress would be a more sensitive index of abnormalities induced by protein calorie deficit, basal concentration of LH, follicular stimulating

Table 1 : Effect of noise exposure on serum testosterone level.

PERIOD OF EXPOSURE TO NOISE	TESTOSTERONE (ng/ dl)	
	CONTROL ®	EXPERIMENTAL
Acute noise exposure		
1 hour	0.65 ± 0.01	0.54 ± 0.002**
3 hours	0.70 ± 0.02	0.38 ± 0.025**
Chronic noise exposure		
60 days - 1 hr	0.65 ± 0.01	0.37 ± 0.016**
60 days - 3 hr	0.69 ± 0.04	0.57 ± 0.020**
90 days - 1 hr	0.67 ± 0.03	0.45 ± 0.012**
90 days - 3 hr	0.65 ± 0.04	0.30 ± 0.01**
EACH VALUE REPRESENTS MEAN ± SEM OF 6 OBSERVATIONS **P<0.01 WHEN COMPARED TO RESPECTIVE CONTROL VALUE. @CONTROL ANIMALS WERE NOT EXPOSED TO NOISE. \$- EXPERIMENTAL ANIMALS WERE EXPOSED TO NOISE EVERY DAY FOR ONE HOUR.		

hormone (FSH) or testosterone (9, 10). Tamoxifen decreased the serum testosterone level and disrupted the testicular seminiferous epithelium (11). The influence of immobilization stress on testicular germ cell apoptosis was investigated in rats. A transient increase in serum corticosterone and a transient decrease in serum testosterone were observed during

each period of immobilization stress (12). Chronic immobilization stress provoked an increase in serum corticosterone which caused the decline in testosterone concentration (13). Pituitary adrenal activity in rats were affected by 85 dB chronic noise stress (6). Stress is believed to influence male reproductive activity (14, 15). Five minutes of high

Chart 1 : Effect of noise exposure on serum testosterone (ng/dl) level.

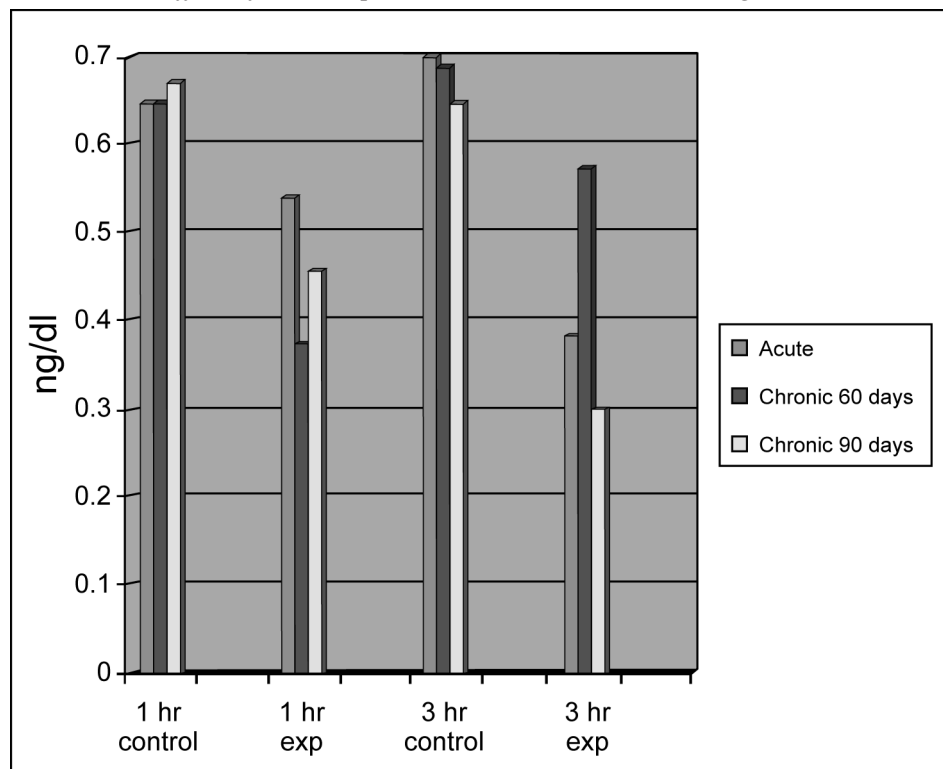
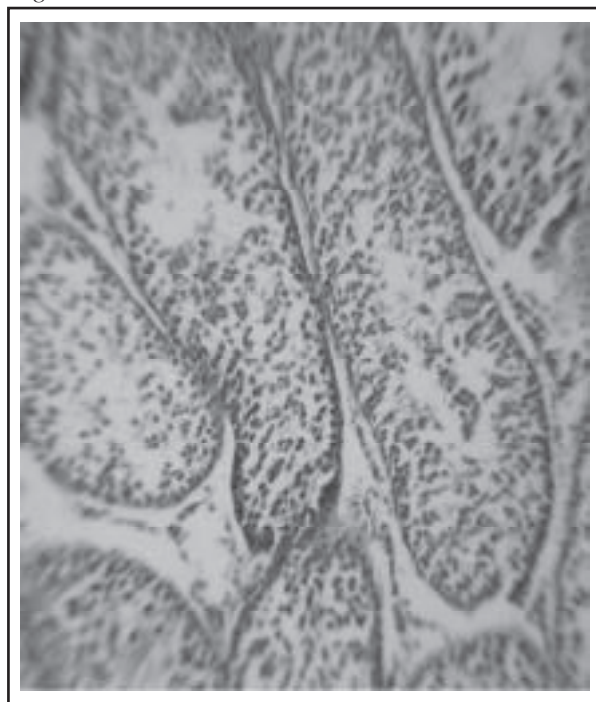


Figure 1 : Control testis scale : 2X X 10X.



power microwave (HPM) radiation might significantly enhance testicular germ cell apoptosis and damage, which in turn might influence the reproductive function of the rats 16). Testicular heat exposure enhanced the suppression of spermatogenesis by testosterone in rats (17,18). Like water stress, heat stress, and immobilization stress, the noise stress also affected the male sex hormone and in turn produced changes in the reproductive organs and glands. Therefore the main objective of

the present study is to investigate the effect of noise stress on the serum testosterone level and on the testicular morphology of Sprague Dawley rats.

Method

The male Sprague Dawley rats weighing 200-250gm were exposed to 100 dB of recorded traffic noise for one hour and three hours in acute group

Figure 2 : 60 Day exeperiment Arrow indicate shrinkage of seminiferous tubules scale : 2X X 10X

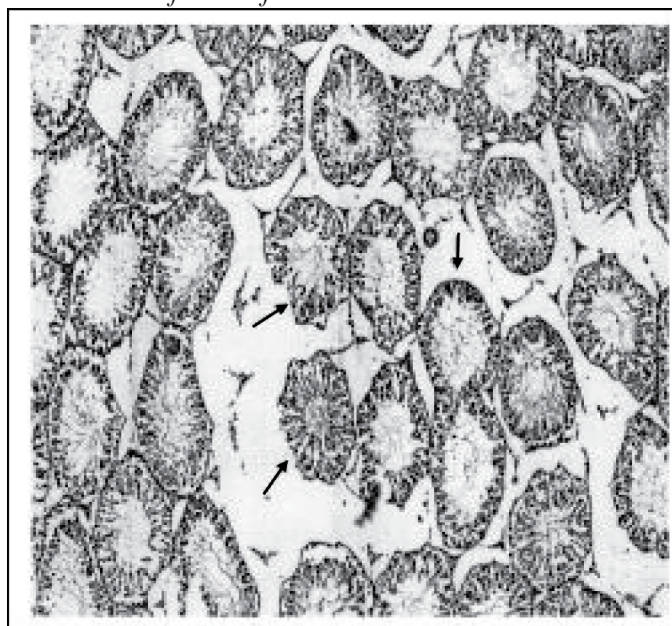
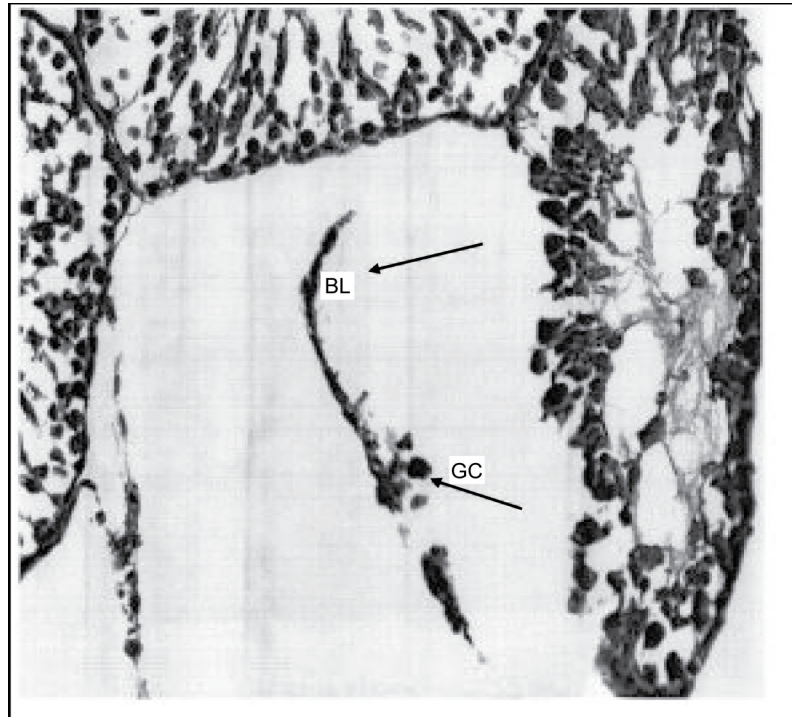


Figure 3 : 60 Day exeperiment Bl. Basal lamina Gc germ cell Scale : 40x x 10x



and daily one hour and three hours for 60 days and 90 days exposure in chronic groups. Their normal habitat was maintained. The animals were exposed to a pure tone noise of sine waves with a frequency of 10,000 Hz and an intensity of 100 dB. sound level decibel meter was used to measure and maintain the intensity of noise. The controls were maintained

and treated like experimental groups in all aspects except exposure to noise. Upon completion of all noise exposure regimens, the animals were anesthetized with an intraperitoneal injection of intraval sodium (60 mg/kg body weight) and exsanguinated. Approximately 5 ml of blood was collected from each rat for testosterone hormonal

Figure 4 : 90 Day exeperiment Progressive shrinkage of semeniferous Tubules scale 2x x 10x

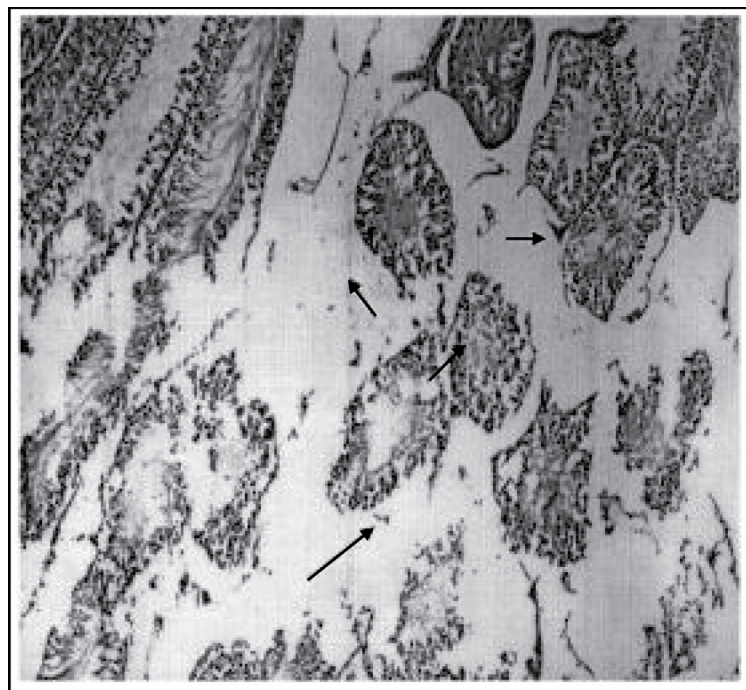
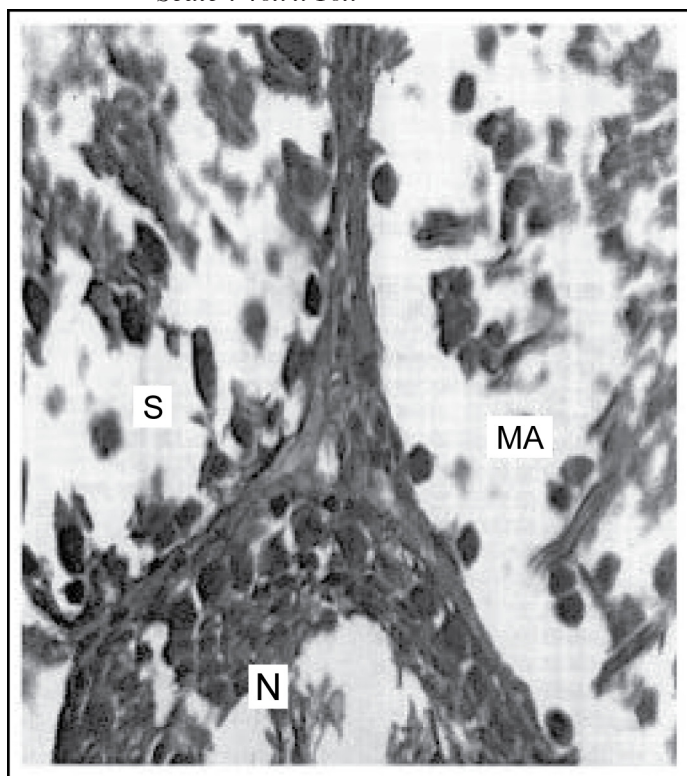


Figure 5 : 90 Day - Maturation Arrest - Ma-Maturation arrest in seminiferous tubule S-Sartolli cell, L-Leydig cell, N-Normal seminiferous tubule, Scale : 40x x 10x



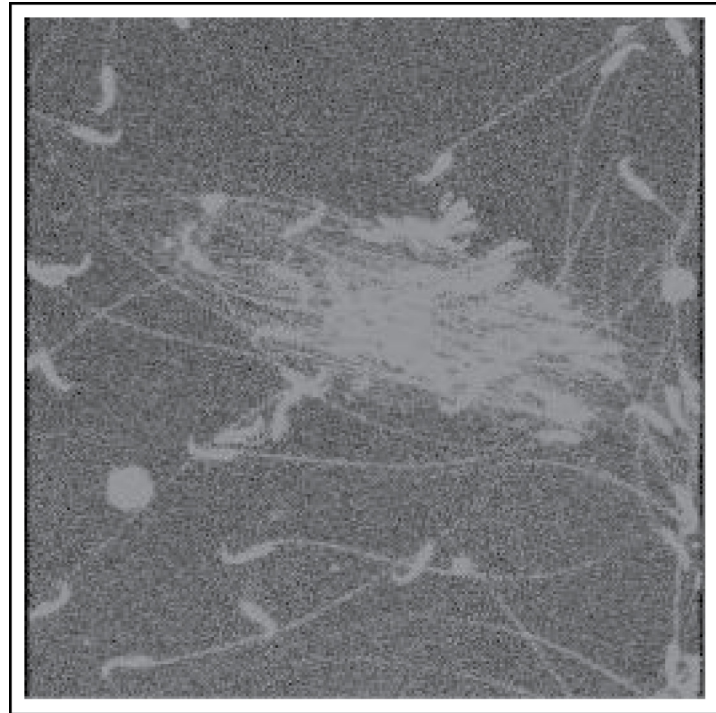
assay, using Elisa method. The DRG Testosterone ELISA KIT IBL HAMBURG, GmbH, GERMANY, was used which was based on the competition principle and the micro plate separation and the kit was stored at 4°C. The separated sample serums were stored at -20° C. The reagents and the specimens were brought to the room temperature before use. On the stipulated day after the collection of the blood for hormonal assay, laparotomy was performed and the testis and epididymides were removed and separated. Tunica vaginalis was carefully removed and the testes were dissected out and cleaned with cold physiological saline to remove blood and the adhering tissues. The samples were then fixed in 10% formaldehyde/in fresh alcoholic Bouin's fluid for 8 hours, and then processed and embedded in paraffin wax. The testis histology was performed according to the method used by Murthy et al (14) The sections were observed under light microscope for qualitative study. This study was approved by the Universiti Sains Malaysia Health Campus Animal Ethics Committee, Kelantan. Ref:PPSG/07(A)/044,2 Desember 2002, (19). The data of the results was subjected to ANOVA followed by Dunner's "t" test for statistical significance. A p

level of <0.05 is considered as statistically significant.

Results

There was a significant reduction in serum testosterone level in acute as well as in chronic noise exposed groups (Table 1, Chart 1). The testis showed normal histological pattern in acute groups (Figure 2). Each testis is subdivided by connective tissue septa into lobules. Each contained numerous highly coiled seminiferous tubules. Each seminiferous tubule is lined by the stratified germinal epithelium, consisting of two major types of cells, the proliferating spermatogenic cells and nonproliferating supporting sustentacular cells or sertoli cells. Surrounding the seminiferous tubules were numerous blood vessels, various connective tissue cells, clusters of epitheloid cells and the interstitial cells of Leydig. Changes were seen in the histological pattern in 60-day (Figure 3,4) and 90-day (Figure 5,6) exposure groups. The seminiferous tubules were shrunken so that there was a space between the septum and the tubules. This type of change was noticed in the central part

Figure 6 : 90 Day - Maturation Arrest Confocal microscopic view shows agglutinated sperms dimensions 512X512



of the tubules only. The peripheral parts of tubules were compact and normal. Moreover maturation arrest in the germinal layers were noticed in some tubules. The basement membrane was broken and the germ cells sloughed into the interstitium. This was more advanced in 90 day exposure group. The sperms in the epididymis showed agglutination both under the light microscopy and confocal microscopy (Figure 8).

Discussion

There was a significant decrease in the serum testosterone level after exposure to 100dB of traffic noise. The secretory response of Leydig cells of the mutant rats were slightly decreased since plasma concentration of testosterone did not increase in response to high concentration of plasma LH (20). This is similar to the invitro testosterone production by Leydig cells of singly housed, timid mice were lower in comparison with those aggressive mice housed in groups. Normally, leutinizing hormone acts on the testes and increases the plasma testosterone level. The follicular stimulating hormone controls the secretion of androgen-binding protein by the sertoli cells. This protein increases the concentration of testosterone in the seminiferous tubules for proper spermatogenesis. Testosterone and follicular stimulating hormone (FSH) suppression

induced spermiation failure (21) is similar in the present study. It may be due to the feed back action of testosterone on the hypothalamus. In chronic noise exposed rats there was maturation arrest in the germ cells due to reduced testosterone level. The Leydig cell proliferation is likely to be a compensatory mechanism to increase testicular steroidogenesis triggered by testosterone insufficiency (22). During stress, the hypothalamic-pituitary-adrenal axis is activated, the glucocorticoid secretion increases (23) and consequently, circulating testosterone levels are decreased via glucocorticoid receptors in Leydig cells. In noise exposed rats the serum testosterone level was reduced which is similar as in immobilization test where the stress did not alter plasma luteizing hormone (LH) levels, but plasma testosterone (T) levels were reduced by 82% (24) which is similar to that of Bambino and Hsueh (25).

Transient increase in serum corticosterone and transient decrease in serum testosterone were observed during each period of noise and immobilization stress. Also enhanced testicular germ cell apoptosis was seen. (23, 26, 27). Low testosterone production (28) adversely affects the quality of ejaculates and subsequent fertility. The decrease in testosterone level is also associated with the marked reduction in epididymal sperm number (22). Moreover the epididymal sperms were agglutinated in noise exposed chronic group and

the number of dead sperms were increased (29). So alterations in the normal testicular morphology associated with maturation arrest in the germinal cells was found and is similar to those findings following DPP treatment (20, 22, 30, 31).

Conclusion

Hence, 100dB of traffic noise exposure of varying duration has definite permanent effect on testicular histology and morphology and on the serum testosterone levels. Alteration in the testosterone levels produces structural changes in testicular tissues during long exposure of 100 dB noise. The adaptation mechanism described by Ogale was noticed in sex hormonal levels in the present study. But there were structural changes in different duration of time in chronic groups seems to be irreversible. Once the structural changes occur, they may not return to normalcy. So, 100 dB of traffic noise has made definite structural changes and maturation arrest in the proliferating germinal cells in testis and increased the dead sperms and agglutinated sperms. This is a sign of infertility. So the agglutinated dead sperms revealed the possibility of infertility in chronic exposure to noise of higher decibels. As such "Noise is a silent killer" (32).

Acknowledgements

This project was carried by short term grant no: 304/P PSP/6131269. I acknowledge the Research Creativity and Management Office, Chancellory, Universiti Sains Malaysia, 11800, Penang, the R and D department, and the Animal Ethics, School of Medical Science Committee. The Dean, Deputy Dean of Research, Universiti Sains Malaysia, 16150, Kubang Kerian Kelantan Malaysia for their kind help and cooperation. My special thanks to Mr. Harrissal, technologist, Department of Anatomy for his cooperation and effort to finish this project. But not least, I thank my husband and my son for their help, moral support, valuable suggestions and contributions to finish this project successfully.

Corresponding Author:

Dr. G Chandralekha
3.A, Quanta Castle, Rangarajapuram Main Road
Kodambakkam, Chennai - 24
Pin code 600 024, Tamil Nadu, India

Tel: +914424833501
Fax: +914424833501
h/p 00919840819631
e-mail : chandrajegan47@yahoo.com

References

1. Collins, (1995). Endocrine dysfunction.
2. Clark DA, Banwatt D, Chaouat G. Stress triggered abortion in mice prevented by alloimmunization. *Am.J Reprod. Immunol.* 1993; **29**: 141-147.
3. Cosa, M., and Cosa, G. Annoyance, disturbance and damage caused by noise and vibration". *Ann Ig* 1989; **1**: 133-156.
4. Nawrot PS, Cook RO, Hamm CW. Embryotoxicity of broadband and high frequency noise in the CD-1 mouse. *J Toxicol Environ ealth.* 1981; **8**: 151-157
5. Prabhakaran, K., Suthanthirarajan, N. and Namasivayam, A. Biochemical changes in acute noise stress in rats. *Indian J. Physiol. Pharma. Co.* 1988; **32**: 100-104.
6. Armario, A. and Castellanos, J.M. Effects of noise stress on testosterone secretion in mice. *IRCS. Med Sci.* 1984; **12**: 208-210.
7. Faldikova L, Diblikova I, Canderle J, Zraly Z, Veznik Z, Sulcova A. Effect of nutrition, social factors and chronic stress on the mouse Leydig cell testosterone production. *Vet.Med-Czech.* 2001; **46**: 160-168.
8. Dong Q, Salva A, Sottas CM, Niu E, Holmes M, Hardy MP. Rapid glucocorticoid mediation of suppressed testosterone biosynthesis in male mice subjected to immobilization stress. *J Androl.* 2004; **25**: 973-981
9. Armario, A., Campany L., Lopez-Calderon A. Pituitary – gonadal function in adult male rats subjected to chronic water restriction. *J. Androl.* 1987; **8**: 1-6
10. De Boer, S.F., Vander Gugten, J., and Slangen J.L. Plasma corticosterone and Catecholamine content induced by low doses of eltamethrine in rats. *Toxicology.* 1988; 263-270.
11. Gopalakrishnan K, Gill-Sharma MK, Balasinar N, Padwal V, D'Souza S, Parte P, et al. Tamoxifen-induced light and electron microscopic changes in rat testicular morphology and serum hormonal profile of reproductive hormones. *Contraception.* 1998; **57**: 261-269.
12. Hiroshi Yazawa, Isoji Sasagawa\ "FN1" \t " _blank" 1, Manabu Ishigooka and Teruhiro Nakada. Effect of immobilization stress on testicular germ cell apoptosis in rats. *Human Reproduction.* 1999; **14**: 1806-1810.
13. Sasagawa I, Yazawa H, Suzuki Y, Nakada T. Arch Androl. Stress and testicular germ cell apoptosis. 2001; **47**(3): 211-216.
14. Murthy NV, Wray SR, Melville GN, Wynter HH, Ram NV, Haran NV. Testicular function in rats following immobilization stress. *Int J Gynaecol Obstet.* 1988; **26**: 297-299.

15. Kobegenova, L.s., Kvanysh bekova, G.A. and Tulegenov, B. Levels of cortico steroids in laxity goats under stress. u. Akael. Nauk. Ka2. Ssr. Sor. Biol. . 1985; 4:75-77.
16. Yu C, Yao Y, Yang Y, Li D.Changes of rat testicular germ cell apoptosis after high power microwave radiation., Zhonghua Nan Ke Xue. 2004; **10**: 407-1
17. Lue Y, Hikim AP, Wang C, Im M, Leung A, Swerdloff RS.Testicular heat exposure enhances the suppression of spermatogenesis by testosterone in rats: the “two-hit” approach to male contraceptive development. Endocrinology. 2000; **141**: 1414-1424.
18. Sailer BL, SarkarB , Sarkar LJ, Bjordahl JA, Jost LK, Evenson DP.Effects of heat stress on mouse testicular cells and sperm chromatin structure. J Androl. 1997; **18**: 294-301.
19. Animal ethics Committee, Kelantan. Ref : PPSG/07(A)/044, 2 Disember 2002.
20. Noguchi.J,m.Yoshida,H.ikadai,T.Imamichi,G. Watanabe. Age-related changes in blood concentrations of FSH,LH and testosterone and testicular morphology in a new rat sterile mutant with heredity aspermia. J Reprod. Fert. 1993; **97**: 433-439.
21. Amanda Beardsel and Beardsley A, O'Donnell L. Characterization of normal spermiation and spermiation failure induced by hormone suppression in adult rats. Biol Reprod. 2003; **68**: 1299-1307
22. Mylchreest E, Sar M, Wallace DG, Foster PM. Fetal testosterone insufficiency and abnormal proliferation of Leydig cells and gonocytes in rats exposed to di (n-butyl) phthalate. Reprod Toxicol. 2002; **16**:19-28
23. Pellegrini, A., Soldani, P., Gesi, M., Lenzi, P., Martin, F.Diazepam reduced ultra structural changes induced by noise stress in rats adrenal gland. Journal of sub microscopic cytology and pathology. 1998; 30: 385-391
24. Orr TE,Taylor MF, Bhattacharyya AK, Collins DC, Mann DR. Acute immobilization stress disrupts testicular steroidogenesis in adult male rats by inhibiting the activities of 17 alpha-hydroxylase and 17,20-lyase without affecting the binding of LH/hCG receptors. Androl. 1994; **15**: 302-308
25. Bambino, T. and Hsueh, A.Direct inhibitory effect of glucocorticoids upon testicular luteinizing hormone receptors and steroidogenesis in vivo and in vitro. Endocrinology.1981; 108, 2142–2148
26. Srivastava, R.K., Taylor, M.F. and Mann, D.R.Effect of immobilization stress on plasma luteinizing hormone, testosterone, and corticosterone concentrations and on 3 β -hydroxysteroid dehydrogenase activity in the testes of adult rats. Proc. Soc. Exp. Biol. Med.1993; **204**: 231–235.
27. Yazawa H, Sasagawa I,Ishigooka M, Nakada T Effect of immobilization stress on testicular germ cell apoptosis in rats. Hum Reprod. **14**: 1806-1810
28. Sapolsky, R.M. (1985) Stress-induced suppression of testicular function in the wild baboon. Role of glucocorticoids. Endocrinology. 1999; **116**: 2273–2278.
29. Chandralekha G, The effect of noise induced stress on the male reproductive endocrine glands of Albino rats,Ph.D thesis, 2002. Dr. M.G.R. Medical University and Research Chennai.
30. Ozguner M , Koyu A, Cesur G, Ural M, Ozguner F, Gokcimen A, Delibas N. Biological and morphological effects on the reproductive orgrans of rats after Exposure to electromagnetic field. Saudi Med J. 2005; **26**: 405-410.
31. Oakes DJ, Webstrer Ws, Brown-Woodman Pd, Ritchie HE. Testicular changes induced by chronic exposure to the herbicide formulatin, Tordon 75D(2,4-dichlorophenoxyacetic acid and picloram) in rats. Reprod Toxicol. 2002; **16**: 281-289
32. Ogale, S.B. ‘Noise overload’ Health and Nutriens.1999; Oct; 85-89