

Lajjalu treatment of uterine prolapse

T. M. Shivanandaiah, T. M. Indudhar

Prakash Clinic, Shivamogga, Karnataka, India

ABSTRACT

Mimosa pudica was found useful in cases of uterine prolapse with bleeding, consistent with my experience of working with the condition for more than 45 years, and treating hundreds of such cases of uterine prolapse. Hysterectomy has been avoided up to this date, and is not now expected to be recommended.

Key words: Ayurveda, uterine prolapse, lajjalu, *Mimosa pudica* linn.

INTRODUCTION

This article is a detailed report of a recent Ayurvedic herbal treatment of Uterine Prolapse, which the senior author has successfully applied in hundreds of cases over the past four decades. Uterine Prolapse is a specific form of the various kinds of genital prolapse common among the female population today, particularly those over 50. While underlying causes may not be clear, what is clear is that physical weakness in that region is quite common.

Biomedical treatment tends to be expensive. For stages 1 and 2, various outpatient treatments including vaginal pessaries^[1] may be prescribed, while for later stages 3 and 4, surgery is usually recommended. Discussions of non-surgical alternatives emphasize that little information is available.^[2] National costs of this lack of alternative are high. In a 2005 study of female hospitalization in the US, Whiteman et al, found gynecological disorders to account for 7% of hospitalizations for women aged 15 to 44, and 14% for those aged 45 to 54.^[3] Of these, the genital prolapse rate was 7.0, a figure that had remained steady for 7 years.^[3]

While hysterectomy is the classic surgical intervention for uterine prolapse, studies show that its application in elderly populations requiring it are not without risk,^[4] particularly when co-morbidity conditions common in the elderly are

present e.g. hypertension, respiratory disease, CVD or DM. Modern alternatives include attempts to rebuild organ walls with porcine skin collagen implant^[5] or polypropylene,^[6] possibly supplemented by such devices as tension-free vaginal tape.^[7] More recent approaches favor minimally invasive^[6] or laparoscopic methods of ligament repair.^[8,9] The latter have been subject to a recent systematic review.^[10]

The cost of these methods, and the inevitable pain and risks involved, make the possibility of a purely herbal alternative highly desirable, both for the patient and the healthcare system. The author has used just such an approach from Ayurveda for several decades. Though not part of the ancient literature, the herb employed, Lajjalu (Sanskrit) (*Pudica Mimosa L.*) is well described in more recent literature dating from 400-500 years ago [Box 1], together with its uses [Box 2].

The following recent case represents a typical example.

CASE HISTORY: LAJJALU USE FOR PROLAPSED UTERUS

A woman aged 44 years reported with a history of vaginal bleeding accompanied by pain, which she said had started a year previously, and had been repeating occasionally. She had been examined at the Medwin Hospital, Banjara Hills, Andhra Pradesh, on 18th June 2009, and advised to wear uterine rings. She was also given medicine to take. She chose not to wear the rings, and only took the medicines.

In her second check on 14 October 2009, an ultrasonogram, found that the condition had aggravated. Subsequent analysis found her Uterine Prolapse to have reached stage 3. Her Gynecologist advised hysterectomy, as the only remedy available. The patient declined the operation, saying

Address for correspondence:

Dr. T. M. Shivanandaiah, Prakash Clinic, D-149,
First Cross, Vidyanagar, Shivamogga - 577203, India.
E-mail: tmshiv@gmail.com

Received: 03-Apr-2010

Revised: 20-Apr-2010

Accepted: 25-Apr-2010

DOI: 10.4103/0975-9476.65090

Box 1: Lajjalu / namskari in ayurvedic literature

1. Ref: Bhavaprakasha Nighantu
Lajjalu sheetala tikta kashaya Kaphapittajit|
Raktapittamateesaram yonirogam vinashayayeth|
Lajjalu (Mimosa pudica L.):
Potency – cold;
Tastes – bitter and astringent;
Normalises vitiated Doshas – Pitta and Kapha;
Cures – bleeding disorders, diarrhoea and diseases of female genitourinary tract
2. Ref: Kaiyyadevea Nighantu
Namaskari Himaatikta Kashayaa kapha pittaha|
Yonirogam ateesara raktapittecha nashayeth
Namaskari (Mimosa pudica L.)
Potency - cold
Taste of drug - astringent and bitter
Can pacify vitiated Doshas - Kapha and Pitta
Cures: diseases of female genito urinary tract, diarrhoea and bleeding disorders.

Box 2: Mode of use

Ref: Sharma DP Vanoushadhi shataka (Hindi). P.177
Yonibhramshaha yonimargse kamal (Garbhashaya; Uterus) bahar ajanepar Lajjalu ke patronka Ras (liquid from crushing) Ya OR mul (Root) Ghiskar kamal par Lep (application) lagaave, aur haatonpar lepkar upar chadave, Langot bhaandkar Aaram karne se kamal rah jaatahai, Naye rog me Laabh hota hai.
In acute uterine prolapse (cervix or uterus is prolapsed through vaginal orifice), application of paste of Lajjalu root and leaves on the prolapsed region followed by application of a tight bandage is beneficial.

she was anemic, and considered herself too weak for the operation. Instead, she visited my clinic in Shivamogga, Karnataka, to try Ayurvedic treatment.

My diagnosis for treatment (as in Figures 2 and 3): complaints were bleeding per vagina - quantity small with bad odor; feeling of a heavy mass in the uro-genital passage; occasional pain in the loins, back and thighs. General examination revealed her to be anemic & emaciated: debility and apathy marked.

Treatment: On the basis of experience, information in Box 3, and with patient's consent, Lajjalu was selected:

Kashayam (Decoction) to be taken orally; and *Swarasa* (liquid/paste from crushing) as external application.

Regime: i). 30ml. *Lajjalu Kashayam* (plant decoction) given 3 times a day for 10 days. The patient found slight improvement in condition; the pain decreased and the bleeding also seemed to be less. ii). an aqueous extract for oral intake was continued along with the external application i.e. a thick paste of Lajjalu root was applied over the Prolapse inside the vagina and a tight diaper was

Box 3: Lajjalu / namskari = *Mimosa pudica* Linnaeus

Family; Mimosaceae. Botany: *Mimosa pudica* Linnaeus
Habitat; Native to tropical America; naturalized in tropical and subtropical regions of India.
English names; Touch-me-not, Sensitive-plant, Humble-Plant.
Ayurvedic Names; *Lajjalu*, *Lajavanti*, *Namaskari*, *Samanga*, *Sanko-chini*, *Shamipatra*, *Khadirka*, *Raktapadi*. (Siddha/Tamil; hottalsurungi.)
Action; Leaf—astringent, alterative, anti-septic, styptic, blood purifier.
Uses: diarrhoea, dysentery, hemophilic conditions, leucorrhoea, morbid conditions of vagina, piles, fistula, hydrocele and glandular swellings.
Root: gravel and urinary complaints Decoction : relief of asthma.
Biochemistry: contains mimosine and turgorin.
Leaf movements: due to derivatives of 4-O- (beta-D-glucopyranosyl-6'-sulphate) Gallic acid.
Aerial parts: contain 2"-O-rhamnosylorientin & 2"-Orhamnosylisoorientin, C-glycosylflavones.
Dosage; Whole plant, root — 10 – 20 ml juice; 50–100 ml decoction.
Central Council for Research in Ayurveda and Sidha (CCRAS).
Whole plant—10–20g for decoction. (API, Vol. II.)

Lajjalu / Namskari in Ayurvedic Literature

1. 'लज्जालुः शीतला तिक्ता कषाया कफपित्तजित् ।
'रक्तपित्तमनिसारं योनिरोगान् विनाशयेत्॥' (भावप्रकश)
2. नमस्करी हिमातिक कषाय कफ पित्ता ।
योनिरोगम् अतिसार रक्त पित्तेचा नाशयेत् ॥ (कैयदेव निघण्टु)
3. 'रक्तपादी शमीपत्रा स्पृष्ट्वा खदिरपत्रिका ।
स्पर्शात् संकोचतां याति पुनश्च प्रसृता भवेत्॥'
(कै. नि.)
4. 'रक्तपादी कटुः शीता पित्तातिसारनाशिनी ।
शोफदाहश्रमश्वासव्रणकुष्ठकफास्त्रनुत् ॥' (रा. नि.)
W. I. VI, 382. Sloka 1,3 & 4 mentioned on
B. B. O., ii, 336 Page 750 Dravyaguna Vijnana
by Priyavrit Sharma,
'Choukambha Bharti Academy
5. योनिभ्रमश्च योनि मार्ग से कमल (गर्भाशय) बाहर
आजानेपर, लज्जालु के पत्रोंका रस या मूल
घिसकर कमलपर लेप लगावे और हाथोपर लेपकर
उपर छडावे, लनोट् भन्धवाकर आराम करनेसे
कमल रहजाता है, नये रोगोंमे लाभ हि होता है ॥
(वनौषधि शतकं हिन्दि पेज नं. १७७ दुर्गाप्रसाद शर्मा)

Figure 1: References from literature

put on, to retain the paste in the contact position for 2 to 3 hours (patients never report any reaction to, or discomfort from, these treatments).

The patient was advised that three 40 day courses of treatment would be needed. The first course began on 11.11.09.

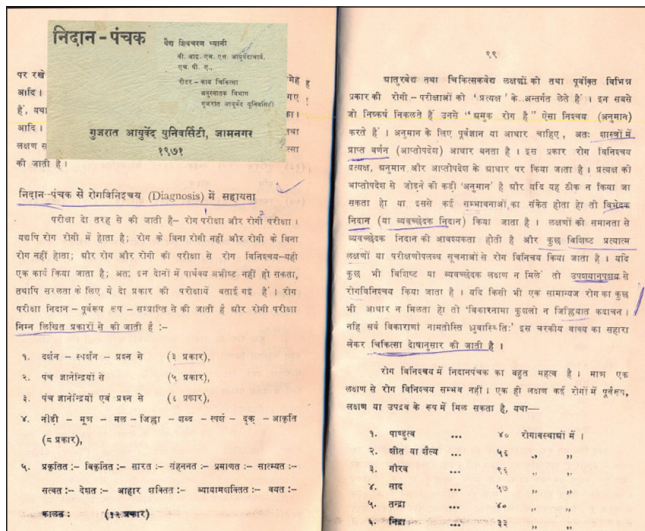


Figure 2: Diagnosis 1

Results 1: on 26.11.09 after 15 days treatment, external and internal, I noted the following:

- Bleeding almost stopped.
- Pain very slight and not continuous.
- Erosion and prolapse markedly reduced; only giving very slight inconvenience.

Results 2: on 28 December 2009, at the end of the first 40 day Ayurvedic treatment, the patient underwent a second Ultrasound Scan. Results were as follows:

Uterus: normal in size, measures 9.5 x 5.5 x 4.3 cm; showing anterior wall intra-uterine fibroid with calcification within it. Suggestive of degenerating of fibroid measuring 1.0 x 0.8 cm.

As on general checkup on 10.10.2009 measures normal white discharge, micturition, no dysuria (painful or difficult urination)

Ovaries: both ovaries now normal in size: echotexture right 2.4 x 2.3 cm; left 2.4 x 2.7 cm.

No evidence of free fluid in pouch of Douglas: no tenderness in the part.

Liver: earlier mildly enlarged in size with increased echo texture.

Now, size is normal, and shows homogeneous echo texture.

Ultrasound Scan of pelvis after completion of 3rd course of treatment: Report Uterus is normal in size and measures 6.6 x 3.3 x 5.2 cm shows small intramural fibroid measuring 9.6mm in anterior wall. Uterine endometrial echo (5.6 mm)

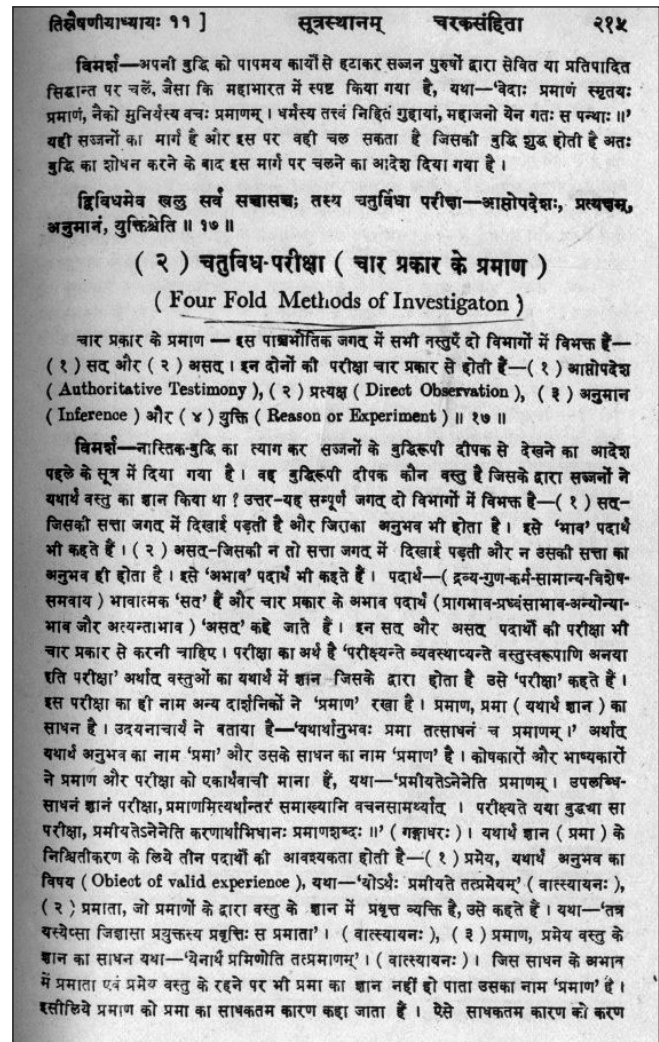


Figure 3: Diagnosis 2

is well visualised and appears normal. 2.6 x 1.8 x 2.7cm. left ovary 2.5 x 1.6 x 2.5 cm. both ovaries are normal in size and echotexture. No evidences of free fluid in Pouch of Douglas.

Clinical Conclusion: Patient's condition shows improvements in several areas.

Also, since the patient had been advised hysterectomy, but being unwilling to undergo surgery, had preferred to try Ayurvedic medicine, it suggests that her first 40 days Ayurvedic treatment may be a step to avoiding hysterectomy (as in findings from my previous treatments).

DISCUSSION

I have treated cases of Uterine Prolapse of different degrees for many years, during which I have presented a few case reports for the benefit of professionals and the

general public. Many patients come from different parts of the country, among them, cases of 2nd and 3rd degree prolapse as diagnosed by Gynecologists. Many such uterine prolapse cases have come to me with scan reports and other details. This article reports a very recent case.

For the entirety of my 50 years medical practice, I have only used Ayurvedic drugs to treat, usually formulated and presented in capsule form for increased convenience over *churna* form. For external application on affected parts, I give *Swarasa* extract, which patients take for lengthy periods, dosage depending on the degree of prolapse.

In addition to uterine prolapse (*Garbha Bhrashta*), Lajjalu is used for prolapsed rectum (*Guda Bhrashta*), vaginal-uterine disorders (*Yoni Vyapat*), dysfunctional uterine bleeding (*Rakta yoni*), piles (*Arsha*), anal fistula (*Bhagandar*), external & internal bleeding & non-bleeding dysmenorrhoea (*Rajah*), leucorrhoea (*Svet Pradara*), & urinary infections.

OVERALL CONCLUSION

Mimosa Pudica was found to be very useful in this case of uterine prolapse with bleeding, consistent with my experience of working with the condition for more than 45 years, and treating hundreds of such cases of third degree uterine prolapse. Hysterectomy was avoided up to this date, and is not now expected to be recommended.

Editorial Comment: As a first single case study by the authors, this was accepted because of its wide potential interest and implications. Today's high prevalence of Uterine Prolapse, and the nature of biomedical treatments, mean that the possibility of wide scale adoption of Lajjalu treatment for that and related problems merits further evaluation.

REFERENCES

1. Hansom LA, Schulz JA, Flood CG, Cooley B, Tam F. Vaginal pessaries in managing women with pelvic organ prolapse and urinary incontinence: Patient characteristics and factors contributing to success. *Int Urogynecol J Pelvic Floor Dysfunct* 2006;17:155-9.
2. Poma PA. Non-surgical management of genital prolapsed: Review and recommendations. *J Repro Med* 2000;45:10-5.
3. Whiteman MK, Kuklina E, Jamieson DJ, Hillis SD, Marchbanks PA. Inpatient hospitalization for gynecologic disorders in the United States. *Am J Obstet Gynecol* 2010. In press.
4. Piya-Anant M, Therasakvichya S, Leelaphatanadit C, Techatrissak K. Integrated health research program for the Thai elderly: Prevalence of genital prolapse and effectiveness of pelvic floor exercise to prevent worsening of genital prolapse in elderly women. *J Med Assoc Thai* 2003;86:509-15.
5. David-Montefiore E, Barranger E, Dubernard G, Detchev R, Nizard V, Darai E. Treatment of genital prolapse by hammock using porcine skin collagen implant (Pelvicol). *Urology* 2005;66:1314-8.
6. Chibeleian B. Minimally invasive surgical treatment of complex genital prolapse in elderly women: Impact on quality of life. *Eur Urol Suppl* 2009;8:664.
7. de Tayrac R, Gervaise A, Chauvaud-Lambling A, Fernandez H. Combined genital prolapse repair reinforced with a polypropylene mesh and tension-free vaginal tape in women with genital prolapse and stress urinary incontinence: A retrospective case-control study with short-term follow-up. *Acta Obstet Gynecol Scand* 2004;83:950-4.
8. Schwartz M, Abbott KR, Glazerman L, Sobolewski C, Jarnagin B, Ailawadi R, *et al.* Positive symptom improvement with laparoscopic uterosacral ligament repair for uterine or vaginal vault prolapsed: Interim results from an active multicenter trial. *J Minim Invasive Gynecol* 2007;14:570-6.
9. Uccella S, Ghezzi F, Bergamini V, Serati M, Cromi A, Franchi M, *et al.* Laparoscopic uterosacral ligaments plication for the treatment of uterine prolapse. *Arch Gynecol Obstet* 2007;6:225-9.
10. Margulies RU, Rogers MA, Morgan DM. Outcomes of transvaginal uterosacral ligament suspension: Systematic review and metaanalysis. *Am J Obstet Gynecol* 2010;202:124-34.

Source of Support: Nil, Conflict of Interest: None declared.